

Full Length Research Paper

Novel expression of the biomarker, N ϵ -hexanoyl lysine in gibberellic acid induced bone toxicity in adult albino rats

Dalia M. Amin^{1*}, Aisha A. Abohashem¹, Ola A. Harb², Walaa M. Sarhan³ and Marwa A. Shabana⁴

¹Department of Forensic Medicine and Clinical Toxicology, Faculty of Medicine, Zagazig University, Egypt.

²Department of Pathology, Faculty of Medicine, Zagazig University, Egypt.

³Department of Medical Biochemistry and molecular biology, Faculty of Medicine, Zagazig University, Egypt.

⁴Department of Clinical Pathology, Faculty of Medicine, Zagazig University, Egypt.

Received 24 February, 2018; Accepted 10 April, 2018

Plants hormones are widely used in agriculture to alter plant characteristics as growth regulators. Gibberellic acid (GA3) plays important role in promoting plant growth, and cell differentiation. This work was performed to investigate the relationship between lipoxidative damage marker (HEL) and bone damage induced by GA3 in adult albino rats. This study was carried out on 20 adult albino rats for 4 weeks treated 6 days/week. The rats were distributed into 2 groups of 10 rats each: Groups I (control) and II (GA3); each rat was treated by GA3 oral gavage (75 ppm) once daily. There was an increase in body and femur weights and length as compared to controls. GA3 caused a decrease in calcium and phosphorus levels in bone while calcium increased and the phosphorus decreased in the plasma. Lipid peroxidation markers caused high femur malondialdehyde levels with decrease in superoxide dismutase, catalase and glutathione peroxidase activities confirmed by histological changes. Immunohistochemical examination for expression of N ϵ -HEL in bone tissues showed strong positive brown reaction in GA3 treated group when compared with control group that showed negative reaction. GA3 toxicity induced bone damage in adult albino rats. It is recommended to increase public awareness regarding the health impact of gibberellic acid.

Key words: Bone, gibberellic acid, lipid per oxidation, N ϵ -hexanoyl Lysine.

INTRODUCTION

Gibberellic acids are plant growth regulators used in agriculture to stimulate growth and development of leaves and stems to increase the production of different crops (Ramwant and Chakrabarty, 2017). In Egypt,

gibberellic acid (GA3) is used widely to increase the growth of strawberries, grapes, tomatoes and cauliflower (Kamel et al., 2009). Occupational exposure to gibberellic acid may occur through inhalation of powder and dermal

*Corresponding author. E-mail: daliaamin013@gmail.com. Tel: 00201013585266.

contact causing various disorders (Fetoui et al., 2006) in humans and experimental rats (Sripaiboonkij et al., 2016).

Although, GA3 induces toxicity to mammalian organs, particularly on breast, bone, lung, kidney and liver (Ustun et al., 1992) of adult mice. Several studies demonstrated that GA3 is associated with cellular damage by oxidative stress and lipid per oxidation in many organs including heart, kidney, lung and bone of adult rats (Celik and Tuluçe, 2007). Bone, rigid organ, may be vulnerable to oxidative stress decreasing bone formation and increasing bone desorption (Ramajayam et al., 2007).

Gibberellic acids induce lipid per oxidation and by reactive oxygen species (ROS) production inducing its toxicity. Monitoring of oxidative damage biomarkers is very essential for estimating health impacts of its exposure and allow early prediction of its hazards. N-epsilon-Hexanoyl-lysine (HEL) is a novel lipid peroxidation biomarker, which is derived from the oxidation of omega-6 unsaturated fatty acid (Celik et al., 2007).

The aim of this study is to determine the effect of GA3 on oxidation of lipids and to investigate the relationship between lipoxidative damage marker (HEL) and bone damage induced by GA3.

MATERIALS AND METHODS

Gibberellic acid was purchased from Berelex®, BDH chemical, Pool, UK. It was provided in a white powder form. Distilled water was used as solvent to the gibberellic acid. Detection kit was also used. The monoclonal antibodies for the specific localization of N epsilon-(hexa- noyl) lysine (HEL) in frozen sections, as well as, in formalin fixed and paraffin embedded tissue were obtained from Medco Pharma Trade Egypt (Ab-4(6A7), Code no. (Ms-714-Po).

Animals

This study was carried on 20 adult albino rats, each weighing 150 g. The study was designed in the Faculty of Medicine, Zagazig University. All animals received care in compliance with the Animal Care Guidelines and Ethical Regulations in accordance with "The Guide for the Care and Use of Laboratory Animals" (Institute of Laboratory Animal Resources, 1996). In order to exclude misconceptions, the following environmental conditions were standardized according to Cuschieri and Backer (1977):

- 1) The climate in the animal house and in the cage with proper ventilation.
- 2) Low noise level was maintained as noise may affect the behavior of the animals.
- 3) The bedding, wood shaving was sufficient to absorb urine and also changed frequently to keep the animals clean.

Accordingly, the animals were kept in galvanized iron mesh cage with solid bottoms, which contained wood shaving as bedding, 10 rats per cage to avoid them been crowded, also, isolation were avoided.

The rats were kept in this environment for two weeks before starting experimentation to be adapted to any possible stress secondary to transportation procedure from the animal supplier or due to sudden environmental modification and exclude any diseased animal

(Semler, 1992). The rats received balanced food, rich in all nutrients necessary to maintain their health before and during drug administration. Distilled water was offered *ad libitum* in separate clean containers.

Study design

This study was done 6 days/week for 4 weeks and the rats were randomly divided into 2 groups of 10 rats each:

1. Group I (control group): Each rat received only regular diet *ad libitum* and distilled water to determine the basic values of performance.
2. Group II (gibberellic acid (GA3) group): Each rat was gavaged orally with 75 ppm of GA3 once daily, 6 days/week for 4 weeks (Celik et al., 2007).

Methods

At the end of the 4th week of the study period, rats from each group were subjected to blood sample collection by means of capillary glass tubes from the retro-orbital plexus under light ether anesthesia as described by Nemzek et al. (2001). The animal was held in the left hand and grasped from the back, while enclosing the neck and exerting slight pressure by the thumb and index fingers. The blood samples were used for estimating the following tests:

Biochemical assays

Plasma calcium and phosphorus levels

Calcium and phosphorus levels were determined in femur and plasma using commercial reagents kits (Biaocon, 2004).

Malonyldialdehyde (MDA) level in bone

This was detected in the femur homogenates by the method of Draper and Hadley (1990) following the reaction of thiobarbituric acid (TBA) with malonyldialdehyde (MDA). The pink color produced was detected spectrophotometrically by ErbaChem 7.

Antioxidant enzyme activities

A) Catalase activity (CAT): This was detected following Aebi (1984) by adding the homogenate hydrogen superoxide (H_2O_2) with phosphate buffer; the changes in absorbance were recorded spectrophotometrically by ErbaChem 7.

B) Superoxide dismutase activity (SOD): this was estimated according to Beauchamp and Fridovich (1971) by adding potassium phosphate buffer, EDTA, L-methionine, riboflavin and nitro blue tetrazolium (NBT). Blue color in the reaction was measured spectrophotometrically by ErbaChem 7.

c) Glutathione peroxidase activity (GPx): This was detected following Flohe and Günzler (1984) procedure. The mixture of phosphate buffer, glutathione (GSH), sodium aside, and H_2O_2 and femur homogenates was prepared. Tubes were centrifuged and the supernatant was collected. The absorbance was recorded spectrophotometrically by ErbaChem 7.

D) Total glutathione level (GSH) in bone: This was determined by

Table 1. A statistical comparison between control group "I" and treated group (GA3) "II" as regard mean values of body weight, femur weight and length after 4 weeks in adult albino rats by Student t test.

| | Duration | (Control) mean \pm SD | GA3(II) mean \pm SD | P |
|-------------------|----------|-------------------------|-----------------------|----------|
| Body weight (g) | 4 weeks | 21.81 \pm 0.55 | 25.08 \pm 0.59 | <0.001** |
| Femur weight (mg) | 4 weeks | 91.12 \pm 11.37 | 95.71 \pm 12.57 | 0.51# |
| Femur length (mm) | 4weeks | 14.41 \pm 0.42 | 13.5370.76 | <0.001** |

SD = Standard deviation; N.B: ** = highly significant; N.B: # = non-significance (P>0.05).

Table 2. A statistical comparison between control group "I" and treated group (GA3) "II" as regard mean values of bone and serum (Ca and Ph) after 4 weeks in adult albino rats by Student t test.

| | Duration | (I) Mean \pm SD | GA3 (II) Mean \pm SD | P |
|------------------------|----------|-------------------|------------------------|----------|
| Bone Ca level (mg/g) | 4 weeks | 101 \pm 9.12 | 78.54 \pm 7.73 | <0.001** |
| Bone P level (mg/g) | 4 weeks | 52.33 \pm 6.65 | 44 \pm 5.29 | <0.001** |
| Plasma Ca level (mg/l) | 4weeks | 71.52 \pm 4.49 | 40.29 \pm 3.82 | <0.001** |
| Plasma P level (mg/l) | 4weeks | 58.46 \pm 4.47 | 40.33 \pm 3.85 | <0.001** |

SD = Standard deviation; N.B: ** = highly significant

the method of Ellman (1959) measuring yellow colour when 5,5-dithio-bis-2 nitro benzoic acid (DTNB) was added with femur homogenate in phosphate buffer, then centrifuged. The absorbance was measured spectrophotometrically by ErbaChem 7.

Tissue sampling

The rats anesthetized by ether were sacrificed by transection of major blood vessels. The femurs were taken for histopathological study. All femur samples were weighed and divided into three pieces for:

1. Estimation of tissue oxidative stress markers (malonyldialdehyde and reduced glutathione)
2. Histopathological studies.
3. Immunohistochemical studies.

Histopathological study by H&E

The bone specimens were fixed in 10% neutral formalin. 5 μ m thick paraffin sections were cut. The obtained sections were stained by Haematoxylin and Eosin (H&E) then examined by light microscope.

Immunohistochemical staining

The tissues were stained immunohistochemically with anti-HEL monoclonal antibody. Briefly, after deparaffinization, the sections were treated with 0.3% H₂O₂ in methanol for 30 min at room temperature, and with 0.1% trypsin for 15 min at 37°C. Then, the sections were reacted with HEL monoclonal antibody (Mouse monoclonal (HNEJ-2) to 4 Hydroxynonenal ab 485061:100) for 4°C overnight, followed by incubation with Dako En Vision/HRP system (Dako, Tokyo, Japan) for 30 min at room temperature. Sections were treated with DAB for 5 min, and counterstained with haematoxylin-eosin for 1 min with the sensitive universal immunostaining kit (Rommer et al., 2004).

Statistical analysis

Statistical significance among groups was determined using the Student's t-test by arithmetical means \pm SEM.

RESULTS

Body weight, femur weight and length

There was significant increase in the weight of rats and femur length in GA3 group when compared with the control group. There was no significant difference between both groups in femur weight (Table 1).

Biochemical results

Calcium and phosphorus levels

There was significant decrease in calcium and increase in phosphorus in the bone in GA3 group as compared to the control group, while, calcium levels significantly increased and phosphorus levels significantly decreased in plasma (Table 2).

Malonyldialdehyde (MDA) level in bone

There was significant increase of bone tissue (MDA) content in GA3 treated rats group when compared with the control group. (Table 3)

Antioxidant enzyme activities

Femur antioxidant enzyme activities significantly

Table 3. A statistical comparison between control group "I" and treated group (GA3) "II" as regard mean values of glutathione peroxidase and malonyldialdehyde after 4 weeks in adult albino rats by Student t test.

| | Duration | Control Mean \pm SD | GA3 (II) Mean \pm SD | P |
|-------------------------------|----------|--------------------------|---------------------------|----------|
| Glutathione peroxidase (mg/g) | 4 weeks | 233.83 \pm 27.51 | 160.83 \pm 24.54 | <0.001** |
| Malonyldialdehyde (nmol/g) | 4 weeks | 27.91 \pm 5.80 | 60.59 \pm 6.93 | <0.001** |

SD = Standard deviation; N.B: ** = highly significant

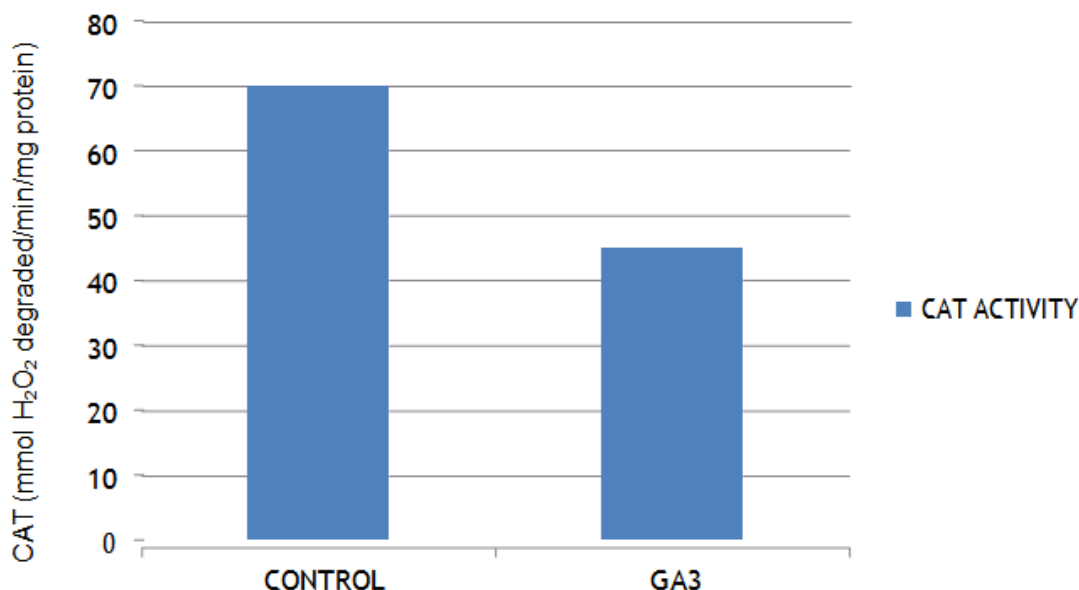


Figure 1. Bar chart showing comparative magnitude of activity of catalase enzymes (CAT) at different groups: control group (I) and gibberellic acid treated group (GA3), after 4 weeks of the study.

decreased in the GA3 treated group as compared to the control group, in the activities of CAT (Figure 1), (SOD) (Figure 2) and (GPx) (Figure 3) in femur homogenates of rats. The results revealed a significant decrease of bone tissue (GSH) in GA3 treated rats as compared to controls (Table 1).

Histopathological study

Histopathological changes of the femur

Light microscopic examination of H&E stained sections from the femur of the control group revealed that, the femur showed normal architecture in the bone of the controls (Figure 4a, b). In gibberellic acid treated group, the sections showed new vessels in greatly developed region and bone trabeculae were fewer, thinner and fragmented as compared to the control group (Figure 5).

Immunohistochemistry examination was done for

detection of HEL protein apoptotic markers that appeared as a cytoplasm reaction brown in color. The stained sections from the femur of the control group showed no immunoreactivity within osteocytes (Figure 6). In gibberellic acid treated group, the sections showed most osteocytes with granular strong +vet brown reaction within cytoplasm (arrows) (Figure 7).

DISCUSSION

Many chemicals contaminate the environment and food including plant growth regulators with many adverse health effects especially bone mineral composition, development in human and rats (Ohn et al., 2017). A plant growth regulator induced reactive oxygen species damage in bone (Troudi et al., 2010). In the present study, there was increase in body weight and femur length as compared to the controls. These results are in agreement with those of Ross et al. (2011) who reported

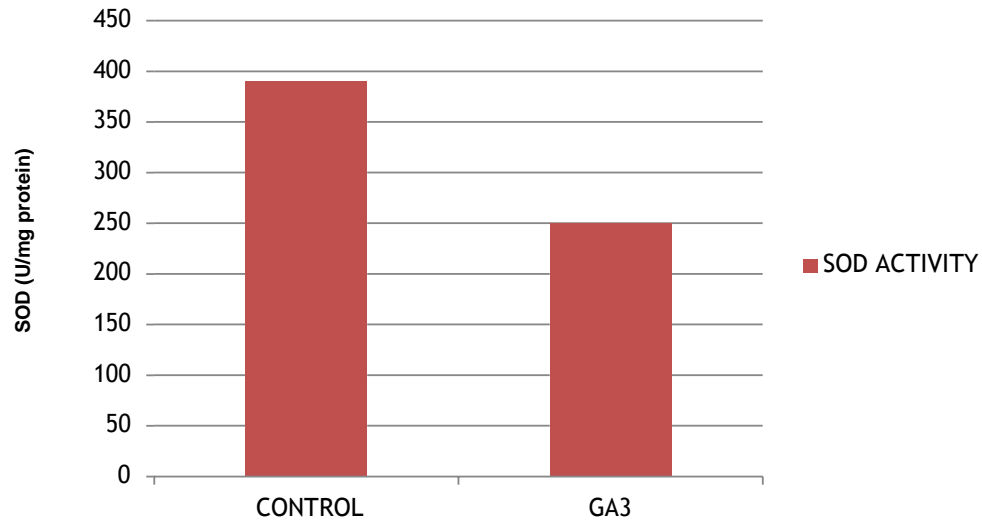


Figure 2. Bar chart showing comparative magnitude of activity of superoxide dismutase enzyme (SOD) at different groups: control group (I) and gibberellic acid treated group (GA3), after 4 weeks of the study.

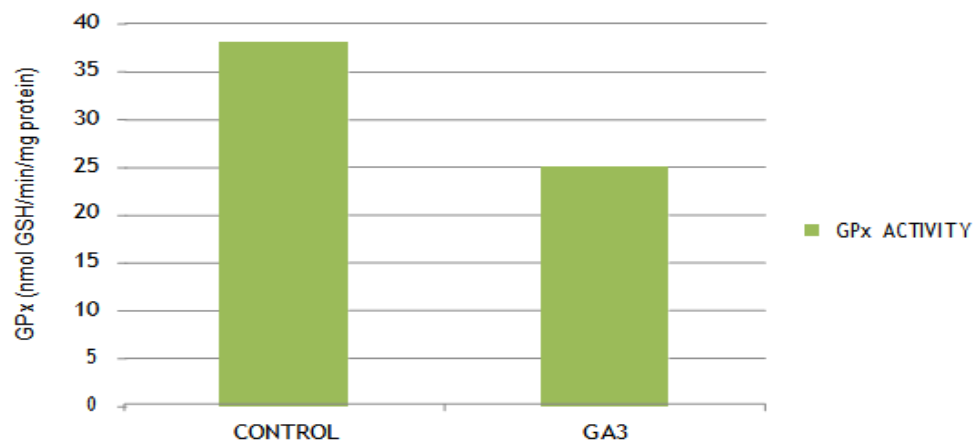


Figure 3. Bar chart showing comparative magnitude of activity of glutathione peroxidase enzyme (GPx) at different groups: control group (I) and gibberellic acid treated group (GA3), after 4 weeks of the study.

that gibberellic acid mechanism by which growth is promoted is guanylate cyclase activation, an enzyme stimulating tissue growth. As shown by Satarug et al. (2004), growth disturbance was due to an increase in food intake by rats.

In this study, there was decrease in bone calcium with increase phosphorus, while there was increase in serum calcium with decrease in phosphorus mean values and decrease in bone (CAT, SOD and GPx) activity and increase in bone MDA level in GA3 treated group as compared to the control group.

These results confirmed are by obvious

histopathological changes in the general architecture of the bone stained with H&E. Also, immunohistochemical staining for detection of HEL protein (apoptotic marker) in bone tissues appear as cytoplasm strong brown reaction. These data are according to Mahijoubi et al. (2005) who detected a disturbed calcium and phosphorus of GA3 treated rats due to the formation of oxygen free radicals in the femur.

Indeed, previous studies showed that the production of free radicals such as H_2O_2 or xanthine oxidase generated superoxide anions which was able to impair osteoblastic maturation in mice (Mody et al., 2001) and marrow cells

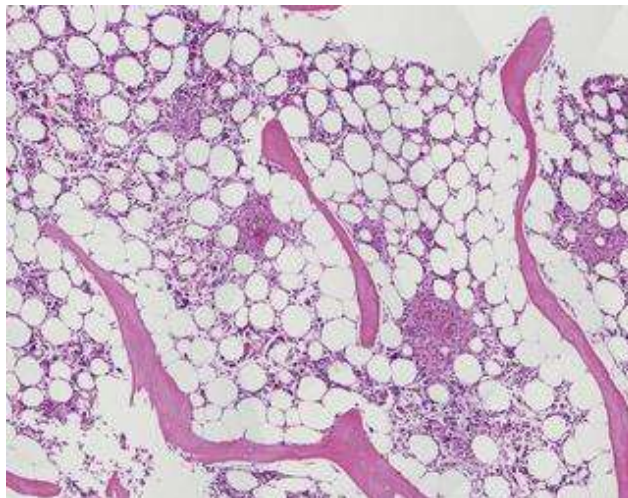


Figure 4a. A photomicrograph of a section in the femur of adult albino rat from the negative control group showing normal bone trabeculae and bone marrow. Stained with hematoxylin-eosin, light microscopy; magnification 100x.

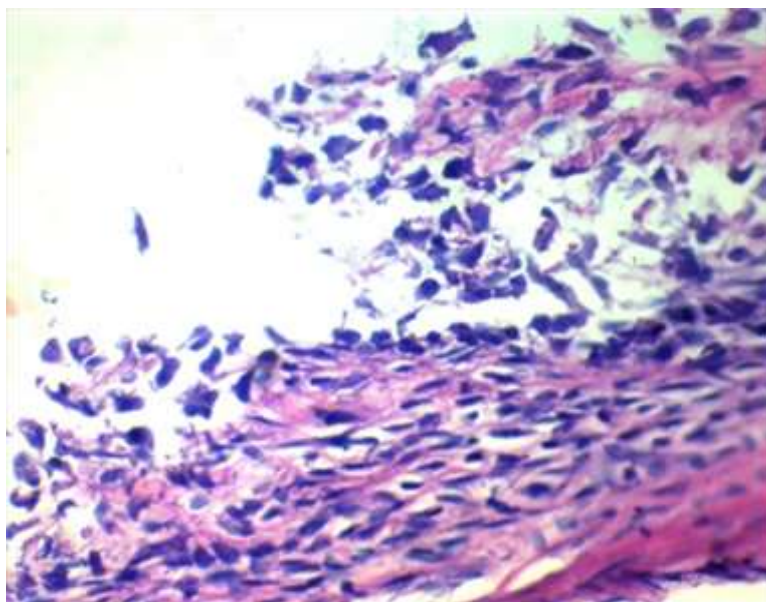


Figure 4b. A photomicrograph of a section in the femur of adult albino rat from the (GA3) treated rats showing fewer, thinner and fragmented bone trabeculae. Stained with hematoxylin-eosin, light microscopy; magnification 400x.

in rabbits (Bai et al., 2004). Nevertheless, these superoxide anions were found to stimulate osteoclast differentiation and bone resorption (Ha et al., 2004; Lean et al., 2004).

These results are also supported by Yavas et al. (2017) who stated that the accumulation of significant amounts of GA3 was previously demonstrated by others in soft tissues like kidney, liver and brain of mice with damaging effect on the antioxidant capacity of reducing glutathione

(GSH), glutathione reductase (GR), superoxide dismutase (SOD), glutathione-S-transferase (GST) and catalase (CAT) activities and increase in lipid per oxidation marker level (MDA).

This result agree with the data provided by Abou-Eisha (2001) who showed that gibberellic acid induced a dose-dependent increase in the level of DNA breakage in human blood cells. Martinez et al. (2017) reported that the mechanism of gibberellic acid induction of DNA

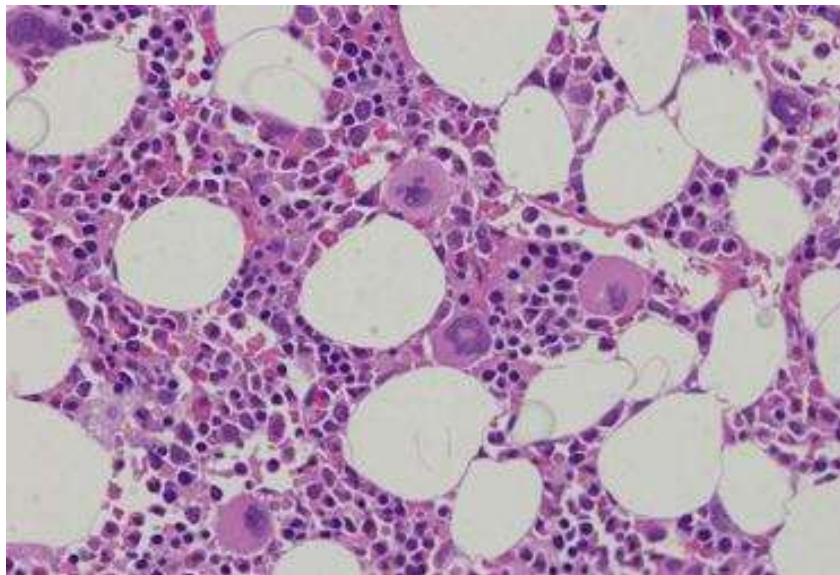


Figure 5. A photomicrograph of a section in the lung of adult albino rat from the negative control group showing normal bone trabeculae and bone marrow, stained with hematoxylin-eosin, light microscopy, magnification 400x.

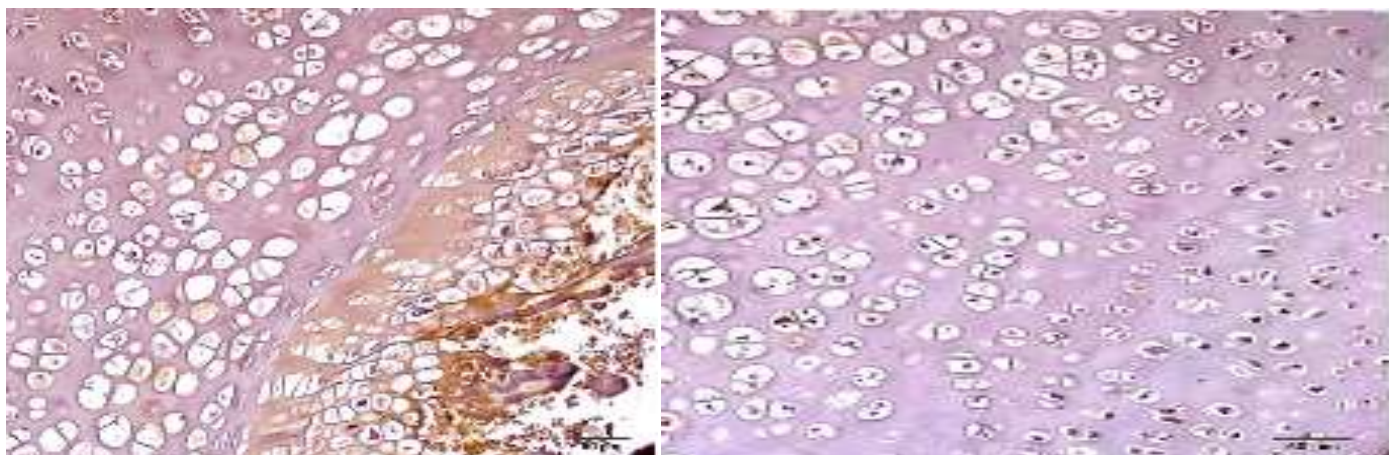


Figure 6. A photomicrograph of a section from the femur of adult albino rat from the negative control group showing negative cytoplasmic (HEL) expression light microscopy, magnification 100x.

damage may be attributed to elevation of oxidative stress markers such as ROS and GSH, Bcl-2 protein expression, mitochondrial membrane potential and caspase-3 activity.

In general, oxidative stress attenuates antioxidant defense system (Ceconi et al., 2003). In this study, the lipid peroxidation marker (MDA) increased in femur of GA3 treated rats. These results are in agreement with Ha et al. (2004), Biaocon (2004) and Hassab-Elnabi and Sallam (2002) who reported an increase of MDA in liver and several tissues like kidney, heart, spleen and lungs in GA3-treated adult rats.

In this study, intense accumulation of N ϵ -HEL

expression in the femur was observed in GA3 exposed rats. The sequel of the release of reactive oxygen species led to mitochondrial membrane depolarization and caspase-3 activation followed by apoptosis (Abou-Eisha, 2001). The formation of N ϵ -HEL has been shown to be a good marker for oxidative stress. In particular, the hydroxyl radical is highly reactive among oxygen radicals. Once excessive hydroxyl radicals cause changes in the fluidity and permeability of membranes, it induces the immunostaining intensity of N ϵ -HEL in lung, bone and heart tissues of rat, showing tendency to increase after gibberellic acid exposure (Ichiseki et al., 2011).

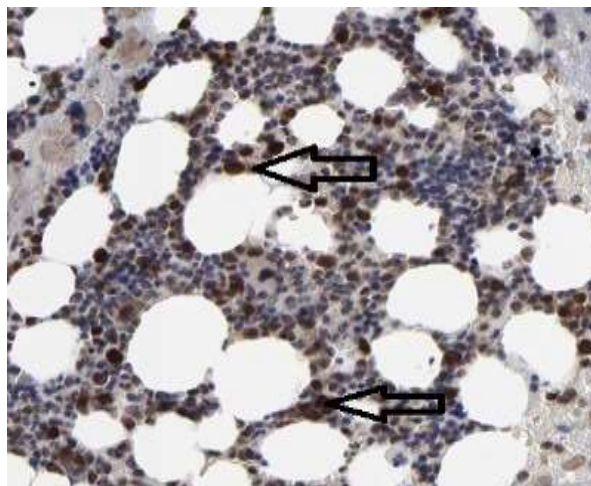


Figure 7. A photomicrograph of a section in the femur of adult albino rat (GA3) treated group showing positive cytoplasmic HEL expression, light microscopy, magnification 400x.

Conclusion

From this study, it is concluded that competent authorities and policies makers should be worked with to regulate the use of these products in order to reduce the application of these chemicals in agriculture and to move to conservative farming.

RECOMMENDATIONS

Improvement of health educational programs for the purpose of increasing public awareness regarding the health impact of gibberellic acid producing oxidative stress and DNA damage on different body organs is recommended. Its use as plant growth regulator with alternative less hazardous chemicals is recommended.

CONFLICT OF INTERESTS

The authors have not declared any conflict of interests.

REFERENCES

- Abou-Eisha A (2001). Evaluation of cytogenetic and DNA damage induced by Gibberellic acid. *Toxicol. Vitro* 20(5):601-607.
- Aebi H (1984). Catalase in vitro. *Methods Enzymol.* 105:121-126.
- Bai XC, Lu D, Bai J, Zheng H, Ke ZY, Li XM, Luo SQ (2004). Oxidative stress inhibits osteoblastic differentiation of bone cells by ERK and NF- κ B. *Biochem. Biophys. Res. Commun.* 314(1):197-207
- Beauchamp C, Fridovich I (1971). Superoxide dismutase: improved assays and an assay applicable to acrylamide gels. *Anal. Biochem.* 144(1):276-287.
- Biaocon M (2004). Malondialdehyde determination as index of lipid peroxidation. *Methods Enzymol.* 186:421-431.
- Ceconi C, Boraso A, Cargnoni A, Ferrari R (2003). Oxidative stress in cardiovascular disease: myth or fact?. *Arch. Biochem. Biophys.* 420(2):217-221.
- Celik I, Tuluze Y (2007). Evaluation of toxicity of abscisic acid and gibberellic acid in rats: 50 days drinking water study. *J. Enzym. Inhib. Med. Chem.* 22(2):219-226.
- Celik I, Turker M, Tuluze Y (2007). Abscisic acid and gibberellic acid cause increased lipid peroxidation and fluctuated antioxidant defense systems of various tissues in rats. *J. hazard. Mater.* 148(3):623-629.
- Cuschieri A, Backer P (1977). *Introduction to Research in Medical Sciences*(1st ed.). By: Cuschieri, A. and Backer, P.P. (eds.). Churchill Livingstone, Edinburgh. pp. 112-120.
- Draper HH, Hadley M (1990). Malondialdehyde determination as index of lipid peroxidation. *Methods Enzymol.* 86:421-431.
- Ellman GL (1959). Tissue sulfhydryl groups. *Arch. Biochem. Biophys.* 82:70-77.
- Fetoui H, Mahjoubi-Samet A, Jammoussi K, Ellouze F, Guermazi F, Zeghal N (2006). Energy restriction in pregnant and lactating rats lowers bone mass of their progeny. *Nutr. Res.* 26(8):421-426.
- Flohe A, Günzler WA (1984). Assays of glutathione peroxidase. *Methods Enzymol.* 105:114-121.
- Ha H, Kwak HB, Lee SW, Jin HM, Kim HM, Kim HH, Lee ZH (2004). Reactive oxygen species mediate RANK signaling in osteoclasts. *Exper. Cell Res.* 301(2):119-127.
- Hassab-Elnabi SE, Sallam FA (2002). The protective effect of ellagic acid against the mutagenic potential of Berelex® in human lymphocyte cultures. *J. Egypt. Germ. Soc. Zool.* 37(C):77-98.
- Ichiseki T, Kaneuji A, Ueda Y, Nakagawa S, Mikami T, Fukui K, Matsumoto T (2011). Osteonecrosis development in a novel rat model characterized by a single application of oxidative stress. *Arthritis Rheumatol.* 63(7):2138-2141.
- Institute of Laboratory Animal Resources (1996). *Guide for the Care and Use of Laboratory Animals.* (7th ed.). National Academy Press. P 125.
- Kamel KI, Elkomy AE, El-Sbeiy ME (2009). The Androgenic Action of Gibberellic Acid (GA3) on Reproductive Performance of New Zealand White Rabbit Bucks. Available at: <https://pdfs.semanticscholar.org/4909/fc4d80515e9f0f153cd2d8f31d756fadda20.pdf>
- Lean J, Kirstein B, Urry Z, Chambers T, Fuller K (2004). Thioredoxin-1 mediates osteoclast stimulation by reactive oxygen species. *Biochem. Biophys. Res. Commun.* 321:845-850.
- Mahjoubi-Samet A, Fetoui H, Boujelben G, Jammoussi K, Ammar E,

- Ellouze F, Guermazi F, Zeghal N (2005). Effects of dimethoate on bone maturation of young rats during the suckling period. *Pestic. Biochem. Physiol.* 83(2-3):132-139.
- Martinez Salgado C, Lopez Hernandez FJ, Lopez Novao JM (2017). Reviews in Mechanistic Toxicology, Glomerular nephrotoxicity of amino glycosides. *Toxicol. Appl. Pharmacol.* 132(7):220-227.
- Mody N, Parhami F, Sarafian TA, Demer LL (2001). Oxidative stress modulates osteoblastic differentiation of vascular and bone cells. *Free Radic. Biol.* 31:509-516.
- Nemzek JA, Bolgos GL, Williams BA, Remick DG (2001). Differences in normal values for murine white blood cell counts and other hematological parameters based on sampling site. *Inflamm. Res.* 50(10):523-527.
- Ohn JA, Blogg CD, Murray FJ (2017). Teratogenic effects of the plant hormone indole-3-acetic acid in mice and rats. *Teratol.* 19(3):321-324.
- Ramajayam G, Sridhar M, Karthikeyan S, Lavanya R, Veni S, Vignesh RC, Ilangovan R, Djody SS, Gopalakrishnan V, Arunakaran J, Srinivasan N (2007). Effects of Aroclor 1254 on femoral bone metabolism in adult male Wistar rats. *Toxicology* 241(3):99-105.
- Ramwant G, Chakrabarty S (2017). Gibberellic acid in plant. *Plant. Signal. Behav.* 1:8-9. <https://www.ncbi.nlm.nih.gov/pmc/articles/PMC4002599/>
- Rommer PS, Dudsek A, Zettl U (2004). Monoclonal antibodies in treatment of multiple sclerosis. *Clin. Exp. Immunol.* 175(3):373-384.
- Ross JJ, Weston DE, Davidson SE, Reid JB (2011). Plant hormone interactions: how complex are they? *Physiol. Plant.* 141(4):299-309.
- Satarug S, Baker JR, Urbenjapol S (2004). A global perspective on cadmium, pollution and toxicity in non-occupationally exposed population. *Toxicol. Lett.* 137:65-83.
- Semler DE (1992). The rat toxicology. In: *Animal Models in Toxicology*. (2nd ed.). By: Gad, S.C. and Chengelis, C.P. (eds.). Marcel Dekker, New York and Hong Kong. Chap: 2. pp. 21-75.
- Sripaiboonkij P, Phanprasit W, Jaakkola MS (2016). Respiratory effects of occupational exposures in a milk powder factory. *Eur. Respir. J.* 31(4):807-814.
- Troudi A, Mahjoubi-Samet A, Zeghal N (2010). Hepatotoxicity induced by gibberellic acid in adult rats and their progeny. *Exp. Toxicol. Pathol.* 6:10.
- Ustun H, Tecimer T, Ozmen M (1992). Effects of gibberellic acid and benzoprenin on mice. *Hispathologic Rev. Ank. Pathol. Bult.* 9:36-40.
- Yavas A, Ozmen M, Topcuoglu FS (2017). Analysis of gibberellic acid, abscisic acid, indole-3-acetic acid and zeatin from selected tissues of albino mice. *Toxicol. Environ. Chem.* 59:251-260.