

Full Length Research Paper

Morphological studies of the appendicular skeleton of the African giant pouched rat (*Cricetomys gambianus*) Part (i) pectoral limb

Salami Sulaiman Olawoye*, Onwuama Kenekwukwu Tobekwukwu, Maidawa Men Sunday, Imam Jibril and Ojo Samuel Adeniyi

Department of Veterinary Anatomy, Ahmadu Bello University, Zaria, Nigeria.

Accepted 19 September, 2011

The pectoral limb of the African giant rat (*Cricetomys gambianus*) was studied using 12 adult rats of both sexes. Characteristics of the bones were studied by gross observation after preparation. Measurements of manus and pectoral limb (articulated) were also taken. The bones of the pectoral limb were found to be generally similar in both structure and number to other rodent species. Variation came only in the size of the bones. The scapula presented a metacromion process in addition to the acromion process. Like in all burrowing mammals, the pectoral girdle presented a rodlike clavicle and coracoids process with tuberos end. The humerus midshaft presented a prominent deltoid tuberosity, while the distal extremity has both the supratrochlear and supracondylar fossae. The radio-ulna bones are fused except at two points (proximal and distal interosseous spaces). Both the radius and ulna ended with styloid processes distally. There are 9 carpal bones with four on the proximal and five on the distal rows, respectively. Each limb presented five digits with three phalanges on each with the exception of the first digit which has two phalanges. The number of bones on each of the pectoral limb was found to be 33 plus 16 sessamoid bones making the total number of 98 bones on the pectoral limb of this rat.

Key words: African giant rat, bones, pectoral limb, manus.

INTRODUCTION

The African giant pouched rat (*Cricetomys gambianus*) is a representative of the family Muridae (Perry et al., 2006), which constitutes a group of the order Rodentia. They are found in Central and West African countries, including Nigeria (Ajayi et al., 1978; Kingdon, 1989). They are the largest murid species occurring in Africa. The Nigerian Wildlife Conservation Committee has encouraged their domestication efforts through breeding, for the purpose of conservation and supplementation of dietary meat supply (Ikede and Ajayi, 1976).

This domestication was also not unconnected with its potential as a good laboratory model, landmine and tuberculosis sniffers (Lindow, 2001; Mekee, 2003; Moth,

2004) as well as the threat posed by the excessive and uncontrolled decimation of this rat for consumption (Dipeolu et al., 1981). Among the unique behaviour of this wild rat is that they are nocturnal, microptic, nearly inactive during the day, but come out at night in search of food (Nowak, 1997). During this inactive period, they live primarily in burrows constructed using their teeth and forepaws to loosen substrate and their hind feet to push excavated soil away (Ewer, 1967). It also has the ability to stand on its hind limbs raising the forelimb off the ground (Ajayi, 1975). Olude et al. (2010) were able to do some preliminary work on the forelimbs without an elaborate exposition of the numerical strength, pictorial clarity and thorough identification of the specific bones. The aim of this study therefore, was to bring to a proper perspective the gross anatomical features of the pectoral limb skeleton of this rat. This will add to the body of information building up on this potentially important wild

*Corresponding author. E-mail: salamiwoye@yahoo.com. Tel: 08030681730.

Table 1. Number of bones that make up the pectoral limb of *C. gambianus*.

Bones per limb	Number
Scapula	1
Clavicle	1
Humerus	1
Ulna	1
Radius	1
Carpals	9
Metacarpals	5
1st phalanx	5
2nd phalanx	4
3rd phalanx	5
Sessamoid bones	16
Total number (33.2%)	49x2=98

Table 2. Lengths of manus and pectoral limb (articulated) of *C. gambianus*.

Skeletal parts	Length	
	Range (cm)	Mean (cm)
Manus	2.8000-3.2000	2.9800±0.08981
Pectoral limb	13.2000-15.0000	13.9250±0.48883

rat.

MATERIALS AND METHODS

A total of 12 adult *C. gambianus* of both sexes were captured alive in the wild around Samaru villages in Zaria, Kaduna state (Nigeria), using metal cage traps. They were then housed in customized laboratory rat cages in the department of Veterinary Anatomy, Faculty of Veterinary Medicine, Ahmadu Bello University, Zaria, Nigeria and fed with fruits, groundnut pellets and water *ad libitum* for a week prior to the commencement of study. The rats were euthanized using gaseous chloroform in a confined container and weighed using a balance (EMPEROR model p.1210) with a sensitivity of 0.1 g. They were then dissected to remove skin, thoracic, abdominal and pelvic contents. The muscles were carefully dissected and teased from the bones to leave the bones with minimal soft tissue attachments, then submerged into different plastic buckets containing 3% Sodium Hydroxide. The plastic buckets were then covered and placed under the sun and checked every 30 min to carefully remove the bones freed of flesh. The bones were then rinsed in water and dried using a fan. Photographs of the bones were taken individually and segmentally in some cases. The total number of bones recovered were counted and recorded. Measurements of the manus and pectoral limb (articulated) were taken.

RESULTS

The pectoral bones of *C. gambianus* were found to be similar to other members of the rat family, but presented some peculiarity in the morphology of some of the bones. Table 1 shows the number of bones on one of the fore limb as well as the total for the two limbs and percentage

**Figure 1.** Clavicle, dorsal view. (1) Sternal end; (2) Body; Acromial end.

of the pectoral limb in relation to the skeleton. The pectoral limb has a total of 98 bones which form 33.2% of the total number of bones that make up the skeleton of this species. Table 2 shows the length of the manus and pectoral limb (articulated). It was observed that there was no sexual dimorphism in the length of the pectoral limb. However, the weights of the rats positively affect the size of each bone.

Pectoral girdle

It presented a rod like, curved, drumstick shaped clavicle (Figure 1).

Scapula

It presented a triangular shaped structure with the cranial border being convex and circular in outline thereby making the cranial angle indistinct. The caudal border was slightly concave with a thick pronounced caudal angle. The scapula spine divided the lateral surface almost equally and extended downward to form the acromion and metacromion processes (Figure 2).

Humerus

It presented two extremities (proximal and distal). The proximal extremity presented a prominent head, well defined neck and two tuberosities separated by an intertuberal groove. It also presented a prominent deltoid tubercle at the middle of the shaft. The distal extremity presented the supratrochlear fossa, olecranon fossa, trochlea, lateral, medial condyles and epicondyles with supracondylar fossa (Figure 3).

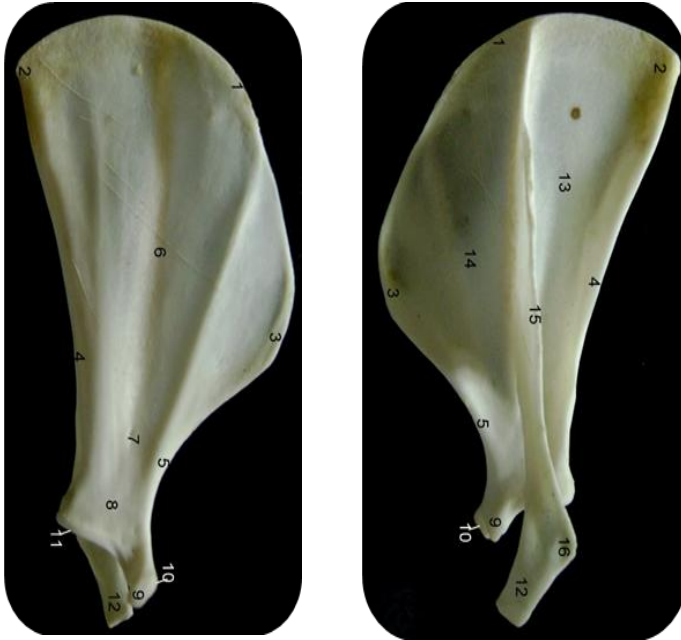


Figure 2. Scapula, medial (L) and lateral (R) views. 1) Vertebral border 2) Cranial angle 3) Caudal angle 4) Caudal border 5) Cranial border 6) Subscapular fossa 7) Nutrient foramen 8) Neck 9) Coracoid process 10) Scapula tuber 11) Glenoid cavity 12) Acromion process 13) Supraspinous fossa 14) Infraspinous fossa 15) Scapula spine 16) Metacromion process.

Radio-ulna bones

The ulna was the longer of the forearm bones, extending from the elbow to the carpus. It got attached to the radius except two points proximally and distally hence presenting a body and 2 interosseus spaces respectively. Each of the two bones ended up distally with a styloid process (Figure 4).

Carpus

It presented a series of 9 rather nodular bones with more or less irregular shapes and flattened articular surfaces. These bones were arranged in two rows of 4 in the proximal and 5 in the distal rows (Figure 5a and b).

Metacarpals and digits

It presented complete metacarpal and digital bones (5 each). All the digits presented 3 phalanges except digit 1 which presented 2 phalanges only. On the flexor surface of each metacarpophalangeal joint are 2 sessamoids. Also on the flexor surface, at the distal end of the middle phalanges are single sessamoid bones. The 1st digit which has only 2 phalanges its distal sessamoid lied at the base of the terminal phalanx (Figure 6a and b).

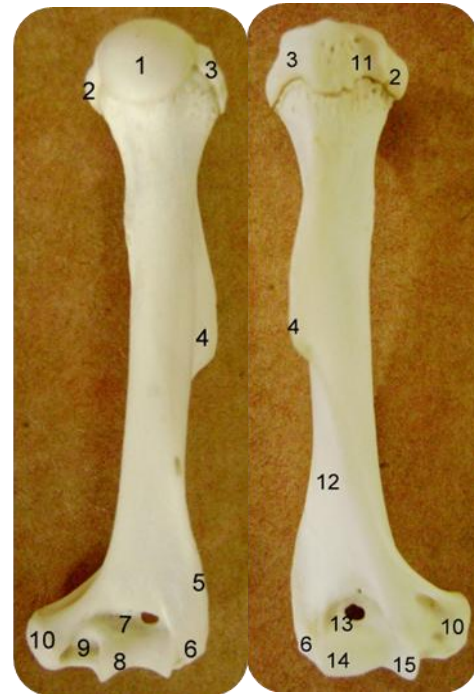


Figure 3. Humerus, caudal (L) and cranial (R) views. 1) Head 2) Lesser tubercle 3) Greater tubercle 4) Deltoid tuberosity 5) Supinator crest 6) Lateral epicondyle 7) Olecranon fossa 8) Trochlea 9) Groove for ulna nerve 10) Medial epicondyle 11) Intertubercular sulcus 12) Musculospiral groove 13) Supratrochlear fossa 14) Lateral condyle 15) Medial condyle.

DISCUSSION

The presence of clavicle in *C. gambianus* is a common feature of the rodent family. It is one of the characteristic of a burrowing animal (Greene, 1968). Its presence has been reported in the guinea pig (Wagner and Mannyng, 1976), rabbit (Ucar et al., 1985) and mole rat (Ozkan, 2002). The scapula, in addition to the acromion process presented the metacromion (hamate) process which projected distally slightly over the glenoid cavity from the scapula spine. The metacromion process has been reported in other Rodentia species (Hebel and Stromberg, 1976; Ozkan, 1997). It has also been reported as a feature of the carnivorous animals (Sisson and Grossman, 1975; Nzalak et al., 2010). It was only in the cat that the suprahamate process reported (Dyce, 2002).

The presence of a prominent deltoid tuberosity in this rat agreed with what was reported for the Muridae family (Saunders and Manton, 1969; Calitlar, 1978; Ozkan, 2002). The distal extremity of the rat's humerus presented supracondylar foramen similar to what was reported for cats (Dyce, 2002). Radius and ulna presented no significant difference from the typical mammalian bones, but contrary to what Olude et al.

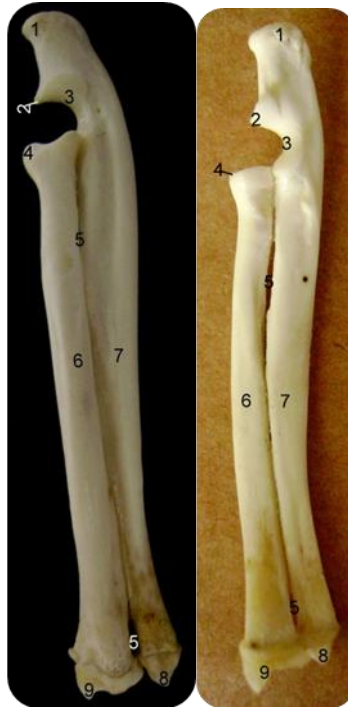

Figure 4. Ulna and radius, lateral (L) and medial (R) views. (1) Olecranon (2) Anconeal process (3) Semilunar notch (4) Coronoid process (5) Interosseous space (6) Radius (7) Ulna (8) Styloid process of ulna (9) Styloid process of radius.

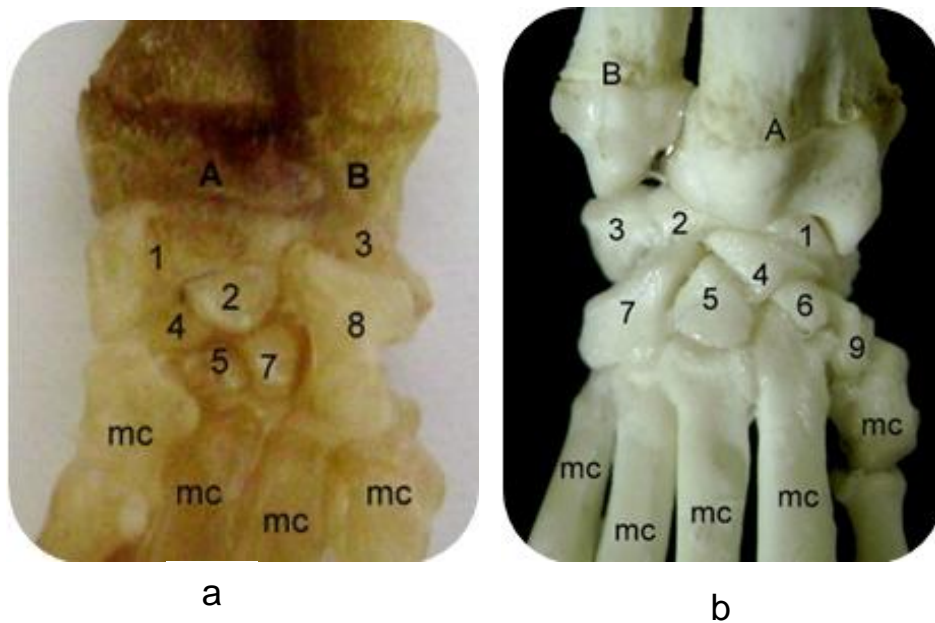


Figure 5. (a) Carpus, volar view. A-Radius; B-Ulna; mc-Metacarpal bone. 1) Navicular 2) Lunate 3) Triangular 4) Centrale 5) Capitate 6) Lesser multangular 7) Hamate 8) Pisiform 9) Greater multangular (b) Carpus, dorsal view. 9 carpal bones (4 proximal and 5 distal rows) and 5 metacarpal bones.

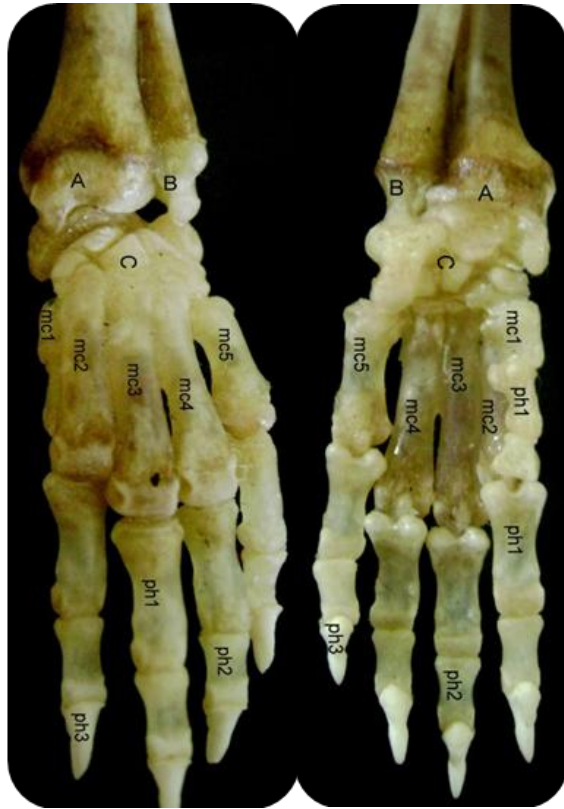


Figure 6a and b. Manus, dorsal (L) and volar(R) views. A-Radius; B-Ulna; C-Carpus; mc1-5: Metacarpals; ph1: First phalanx; ph2: Second phalanx; ph3: Third phalanx.

(2009) reported that the two bones were not fused in some of their specimens. It was observed in this investigation that the two bones were fused except at points which gave rise to the proximal and distal interosseous spaces. The presence of styloid process at the distal end of these two bones resembled what was reported in dog and cat (Miller, 1964; Dyce, 2002).

The number and arrangement of the manus was typical of the Rodentia order and agreed with the work of Greene (1968) on the albino rat. The arrangement of the carpal bones into two rows with the number of bones in the proximal row being less by one to those of the distal row agreed with what was reported in other mammals such as horse, pig, dog, cat and ruminants (Sisson and Grossman, 1975). The observation of five digits in this rat was consistent with what was reported in other rodent species (Saunders and Manton, 1969; Demy'rsoy, 1997, 1998). The arched and pointed shape of the distal phalanges as observed in this study and reported for the hind limb are for easy burrowing and shovelling (Olude et al., 2009, 2010). This study tried to present the peculiar morphology and number of the African giant rat pectoral limb bones. The information herein would add to the body of information gradually building up to enhance the domestication of this valuable rat.

ACKNOWLEDGEMENT

The authors acknowledge and appreciate the assistance of staffs of Gross Anatomy Laboratory, Department of Veterinary Anatomy, Ahmadu Bello University Zaria, Nigeria.

REFERENCES

- Ajayi S, Tewe O, Faturoti E (1978). Behavioural changes in African giant rat (*Cricetomys gambianus*, Waterhouse) under domestication. *East Afr. Wildl. J.*, 16: 137–143.
- Ajayi SS (1975). Observations on the biology, domestication and reproductive performance of the African giant rat *Cricetomys gambianus* waterhouse in Nigeria. *Mammalia*, 39: 343-364.
- Çalıtıllar T (1978). Laboratuvar Hayvanları Anatomisi. Fy'rat Üniv. Vet. Fak. Yay. 14, Ankara Ün. Basy'mevi, Ankara, pp. 106-123
- Demy' Rsoy A (1998). Yay'amy'n Temel Kurallary'. Meteksan AT, Ankara, pp. 33-76.
- Demy'Rsoy A (1997). Türkiye Omurgaly' lary'. Memeliler, Meteksan AT, Ankara, pp. 83-105
- Dipeolu OO, Akinbode OA, Ogunji F (1981). Observation on the African giant rat (*Cricetomys gambianus*). *Bull. Anim. Health Prod. Afr.*, 29: 393-397.
- Dyce KM, Sack WO, Wensing CJG (2002). *Veterinary Anatomy*. WB Saunders Company, Philadelphia, 3: 76-81.
- Ewer RF (1967). The behaviour of the African giant rat (*Cricetomys gambianus waterhouse*). *Zeitschrift fur tierpsychologie*, 24: 6-79.
- Greene CE (1968). *The anatomy of the rat: Transactions of the American Philosophical Society*. New Series. Hafner Publishing Company, New York, London. gross anatomisi üzerinde incelemeler. *Firat Ün Sag Bil Derg*, 27(11): 171-175.
- Hebel R, Stromberg M (1976). *Anatomy of the laboratory rat*. Williams and Wilkins Company, Baltimore, MD., pp. 106-132
- Ikede BO, Ajayi S (1976). Pathological condition of the giant rat (*Cricetomys gambianus*, Waterhouse) in captivity. *J. NVMA*, 5: 63–65.
- Kingdom J (1989). *East African Mammals*. London, New York: Academic Press, pp. 54–57.
- Lindow M (2001). The landmines – Sniffing Rats of Mozambique. *Time Magazine*. Retrieved on 2008-06-23.
- Maidawa SM, Ibe CS (2010) *Gross Anatomical Studies of the Bones of the Thoracic Limbs of the Lion (Panthera leo)*
- Mekee, M (2003) Giant rats to sniff out tuberculosis. <http://www.newscient.Com/article.nsd=dn4488>.
- Miller ME (1964). *The Anatomy of the Dog*. W.B. Saunders Co. Philadelphia, pp. 64-78.
- Moth M (2004). Bees giant African rat used to sniff landmines. http://www.nationalgeographic.com/news/2004/02/0210-040210mine_rats.
- Nowak R (1997). *Mammals of the World*, Available at <http://www.press.jhu.edu/books.html> (accessed 28 March, 2009).
- Nzalak JO, Eki MM, Sulaiman MH, Umosen AD, Salami SO, Olude MA, Olopade JO, Akinloye AK, Mustapha OA (2010). Macro-anatomical investigations of the skeletons of the African giant rat (*Cricetomys gambianus* Waterhouse): Forelimb. *Eur. J. Anat.*, 14: 19-23.
- Olude MA, Olopade JO, Mustapha OA (2009). Macro-anatomical investigations of the skeletons of the African giant rat (*Cricetomys gambianus* Waterhouse): Pelvic limb. *Eur. J. Anat.*, 13: 127-131.
- Özkan ZE (2002). Macro-anatomical investigations on the forelimb skeleton of mole rat (*Spalax leucodon* Nordmann). *Vet. Arhiv.*, 72: 91-99.
- Özkan ZE, Dinç G, Aydın A (1997). Tavşan (*Oryctolagus cuniculus*) kobay (*Cavia porcellus*) ve ratlarda (*Rattus norvegicus*), scapula, clavicula, skeleton brachii ve skeleton antebraçhii'nin karşılaştırılması
- Perry ND, Hanson B, Hobgood W, Lopez RL, Okraska CR, Kararem K, Damon IK, Carroll DS (2006). New invasive species in southern Florida: Gambian rat (*Cricetomys gambianus*). *J. Mammol.*, 87: 262-264.

Saunders JT, Manton SM (1969). A manual of practical vertebrate morphology. Clarendon Press, Oxford, 4: 208-286.

Sisson and Grossman (1975). The anatomy of the domestic animals, 88-177.

Uçar Y, Öcal M, Hazirolu M (1985). Makro-anatomische Untersuchungen über die Clavicula des einheimischen Hundes, der einheimischen Katze und des Neuzelandschasens. J. Fac. Vet. Med. Univ. Ankara, 32: 42-52.

Wagner JE, Manning PJ (1976). The Biology of the Guinea Pig. Academic Press, New York, San Francisco, London, 10-44.