

Full Length Research Paper

***Malassezia pachydermatis* presence in canine external otitis and dermatopathies**

Nascente, P. S.¹, Meinerz, A. R. M²., Faria, R. O²., Nobre, M. O²., Escareño, J. J. H³.,
Mendes, J. F.^{2*}, Meireles, M. C. A.² and Mello, J.R.B.⁴

¹Departamento de Parasitologia e Microbiologia, Instituto de Biologia, Universidade Federal de Pelotas, Pelotas, RS, Brasil.

²Faculdade de Veterinária – Universidade Federal de Pelotas – Pelotas – RS – Brasil.

³Departamento de Microbiologia - Facultad de Medicina Veterinaria y Zootecnia - Universidad Autonoma de Nuevo Leon – Monterrey - México.

⁴Programa de Pós Graduação em Ciências Veterinárias - Universidade Federal do Rio Grande do Sul, Porto Alegre, RS, Brasil.

Received 27 April 2015; Accepted 10 June 2015

***Malassezia pachydermatis* is a commensal yeast of the skin and external ear canal of dogs and cats that may become an opportunistic pathogen under some conditions. The aim of this paper was to research the diseases which predispose to the development of opportunistic *M. pachydermatis* in dogs with external otitis or dermatopathies. The samples were collected by sterile swabs or by the carpet technique. Samples were obtained from the external ear canal and cutaneous tegument and were seeded in Sabouraud dextrose agar added with chloramphenicol and cycloheximide. Following, they were incubated at 32°C for seven days for yeast identification. *M. pachydermatis* isolation was successful in 49 (70%) of the 70 samples investigated. Underlying diseases diagnosed in these animals included ceruminous otitis, skin fold pyoderma, seborrhoeic dermatitis, atopic dermatitis, pressure point pyoderma, parasitic otitis, acanthosis nigricans, hot spot and bacterial otitis. The results confirm that the presence of this yeast can cause the perpetuation of these diseases and be a treatment complication factor.**

Key words: Malasseziosis, dogs, otitis external, dermatopathies.

INTRODUCTION

M. pachydermatis is both normal occurrence yeast and an opportunistic pathogen of the external ear canal of dogs and cats which can also be found on the skin, in the rectum, anal sacs and vagina (Bond et al., 1996; Dizotti and Coutinho, 2007). This yeast is one of the most frequent

microorganisms associated to external otitis in dogs (Gentilini et al., 1991; Crespo et al., 2002; Nascente et al., 2004); recent studies have also referred to *M. pachydermatis* as being the cause of canine dermatitis (Nardoni et al., 2007; Leite et al., 2003).

*Corresponding author. E-mail: josiara.mds@hotmail.com.

Malasseziosis clinical manifestation installation indicates an alteration in the balance between the commensal and its host. The clinical disease occurs when there is an excessive multiplication of *M. pachydermatis* due to alterations in the host defense mechanism. The increase in *M. pachydermatis* cell number is facilitated when there are microenvironment changes, such as an excessive production of cerumen after therapy involving the use of antibiotics or corticoids (Ashbee, 2007; Nardoni et al., 2005), and also by concomitant primary conditions, such as hypersensitivity to food, flea bite hypersensitivity and/or atopy, pyodermitis, demodicosis and endocrine problems (hyperadrenocorticism, hyperthyroidism, diabetes mellitus) (Bond et al., 2002).

The aim of this paper was to research the diseases which predispose to the development of opportunistic *M. pachydermatis* in dogs with external otitis or dermatopathies.

MATERIALS AND METHODS

The study was performed in 70 dogs with dermatological clinical signs and/or external otitis, classified according to age, sex, and breed. All animals were submitted to a general clinical examination; the external ear canal and/or cutaneous tegument were also examined. Auxiliary examination methods were used to reach a final diagnosis.

Cerumen samples from animals with external otitis were collected with sterile swabs, rubbing the anterior part of the ear canal; samples from animals with dermatopathies were collected through the carpet technique (Mariat and Adan-Campos, 1967) by rubbing the carpet in the lesion area.

A direct examination was performed for the material collected from the external ear canal by using Gram coloration, which was analyzed under a microscope (1000X) in search for cells with morphology compatible to *M. pachydermatis*. Direct examination was done by counting the cells which were similar to the yeast in the microscopic field; six fields were observed.

The yeast cell/field absence was considered negative (-), and the following scores were considered positive: (+) up to five cells/field; (++) six to ten cells/field; (+++) more than ten cells/macrosopic field. All isolated samples of *M. pachydermatis* were cultured in Sabouraud dextrose agar medium (kindo et al., 2004; Prado et al., 2008) added with chloramphenicol and cycloheximide kept at 32°C for ten days; their macroscopic characteristics were observed daily. Cell morphology was seen through colony smear, stained with Gram color and then biochemically characterized (Guého et al., 1996).

The results were coded according to animal characteristics parameters (sex, age and ear shape), direct examination and isolation; subsequently, data were analyzed by the EpiInfo software (Epi Info (TM) software), and distribution frequencies were carried out by the chi-square test for comparison.

RESULTS

The samples studied (70) included 26 female and 44 male animals ranging from seven months to 14 years of age, 42 of which belonged to the following breeds: Poodle (7), Cocker Spaniel English (9), Basset Daschund

(5), Sharpei (5) Labrador Retriever (5), German Shepherd (3), Rotweiller (2), Boxer (2), Bulldog (2), Old English Sheep Dog (1) Siberian Husky (1); the remaining 28 animals were mixed breed (MB). External otitis diagnosis was confirmed in 45 dogs (28 male and 17 female) and dermatopathies occurred in 25 dogs (16 male and 9 female) (Table 1).

M. pachydermatis was isolated in 49 (70%) of the 70 samples investigated. The frequency of the yeast isolation was greater (80%, 36/45) for external otitis samples than for dermatitis samples (52%, 13/25) (Figure 1). In all external otitis samples where the yeast was isolated (36), the presence of yeast-like cells was observed by direct examination. Seven samples (15.6%) were scored +, 19 (42.2%) ++, and 10 (22.2%) +++. As to the remaining nine samples without *M. pachydermatis*, four of them (8.9 %) were positive (+) and the other five (11.1%) were negative upon direct examination (Table 2).

Underlying diseases diagnosed in all 70 animals referred to the dermatological clinic were predominantly ceruminous otitis (35), followed by seborrhea (10) and parasitic otitis (6). *M. pachydermatis* was isolated, respectively, in 29 (82.9%), 6 (60%) and 3 (50%) of these illnesses.

Skin fold pyoderma (2), atopy (2), flea bite hypersensitivity (4), hot spot (2), bacterial otitis (2) atopic otitis (2), pressure point pyoderma (1), sarcoptic scabies (1), pododermatitis (1), folliculitis (1) and acanthosis nigricans (1) were also detected. In atopic otitis (2) and bacterial otitis (2), the isolation of *M. pachydermatis* was successful in all samples. There was no isolation of this yeast in animals which showed sarcoptic scabies, flea bite hypersensitivity and pododermatitis. The yeast was isolated in folding dermatitis (2), pressure point pyoderma (1), acanthosis nigricans (1), hot spot (2) and atopy cases (2), *M. pachydermatis* was isolated from one sample only (Figure 2).

In this study, 28 samples of mixed breed animals and 42 definite breed ones were analyzed. Due to the great number of samples obtained from the mixed breed animals (MB), *M. pachydermatis* frequency was high (67.9%) among them. In definite breed dogs, *M. pachydermatis* was isolated in 50% (21), mainly Poodle (85.8%), Daschund (80%), Cocker Spaniel English (77.8%), Sharpei and Labrador retriever (60%) and German shepherd (33.3%) breeds (Table 3).

DISCUSSION

The high *M. pachydermatis* percentage (80%) in canine external otitis cases was similar to those previously found by Gentilini et al. (1991) and Nascente et al. (2004), who found 91.8 and 76.5%, respectively. Feigl et al. (1981), isolated *M. pachydermatis* in 50.6% of

Table 1. Features of the animals referred to veterinary clinic with skin disease or otitis external and its isolation *Malassezia pachydermatis*

Disease	Sex	Age	Race	Base disease	Isolation of <i>M. pachydermatis</i>	
Dermatopathies	16 M 9 F	Seven months to 14 years of age	Poodle (7) Cocker Spaniel English (9) Basset Daschund (5) Sharpei (5) Labrador Retriever (5) German Shepherd (3) Rotweiler (2) Boxer (2) Bulldog (2) Old English Sheep Dog (1) Siberian Husky (1) Mixed breed (MB) (28)	Skin fold pyoderma (2)	13 +	
				Hot spot (2)		
				Flea bite hypersensitivity (4)		
				Atopy (2),		
				Pressure point pyoderma (1)		
				Sarcoptic scabies (1)		
				Pododermatitis (1)		
				Acanthosis nigricans (1)		
				Folliculitis (1)		
				Atopic otitis (2)		36+
				Bacterial otitis (2)		
				Parasitic otitis (6)		
				Ceruminous otitis (35)		
Total	70 (100%)	70 (100%)	70 (100%)	70 (100%)	49 (70%)	

external otitis cases. In other countries, the yeast frequency ranged from 23% to 76.3% (Nascente et al., 2004; Dworecka-Kaszak et al., 1994).

Studies have demonstrated that *M. pachydermatis* frequency is variable and that the high percentage of isolations obtained was probably related to the great number of ceruminous otitis cases, which promotes an accumulation of secretion and cerumen (Nagata, 2013). The latter is a growth promoter to *M. pachydermatis* (Gabal, 1988); this frequency tends to be lower in bacterial otitis (Kiss et al., 1997) even though the yeast was isolated in the two cases presented in this study. It is also important to consider that the presence of the yeast in the external ear canal of dogs is more frequent than that in other parts of the body (Nascente et al., 2004; Guého et al., 1996; Bond et al., 2006; Machado et al., 2003).

In this study, there was a variation in cell number of the collected material from canine external otitis per microscopic field visualized by direct examination; in all cases where *M. pachydermatis* was isolated, however, direct examination presented yeast cells ranging from + to +++. Bond et al. (1996) considered the presence of many yeast cells per microscopic field to be a pathogenic activity sign.

Canine tegument infection by *Malassezia* is a chronic evolution dermatopathy because of the exacerbated multiplication of *M. pachydermatis* in certain cutaneous areas. When there is a rupture of the epidermal barrier, secondary infections caused by bacteria or yeasts may occur. There is a number of cutaneous or systemic conditions that can alter the protective skin barrier, such as food hypersensitivity, atopy, flea bite hypersensitivity, pyodermitis, demodicosis and

endocrine problems (hyperadrenocorticism, hypertireoidism, mellitus diabetes), directly contributing to the development of the disease (Gabal, 1988; Larsson et al., 1998; Nagata, 2013).

M. pachydermatis has also been isolated in animals with skin ceratinization disorders, hypersensitivity, epidermal displasia, and immunosuppression, in addition to those showing external otitis. From the 25 dermatopathy samples, isolation was observed in 52% (13) of the cases, and the underlying diseases diagnosed in these cases were seborrhea (6), folding dermatitis (2), hot spot (2), atopy (1), callus pyodermitis (1) and acanthosis nigricans (1). However, the fact the seborrhea was the most frequent dermatopathy found in the diagnosis (10) must be taken into consideration. The yeast pathogen has been discussed in several studies which have

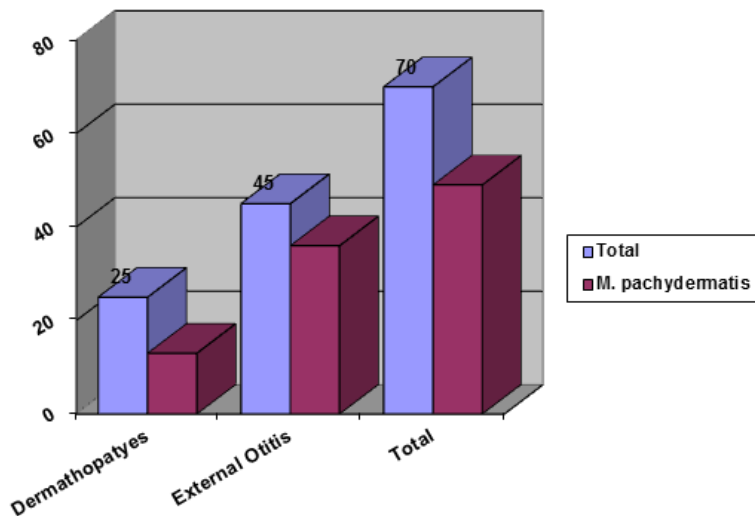


Figure 1. *M. pachydermatis* distribution associated to external otitis and dermatopathies.

Table 2. Distribution of insulation number in relation to the result of the direct examination of cerumem cases of canine otitis external.

Score direct exam	Number of external otitis	Isolation
-	5	
+	11	7
++	19	19
+++	10	10
Total	45	36

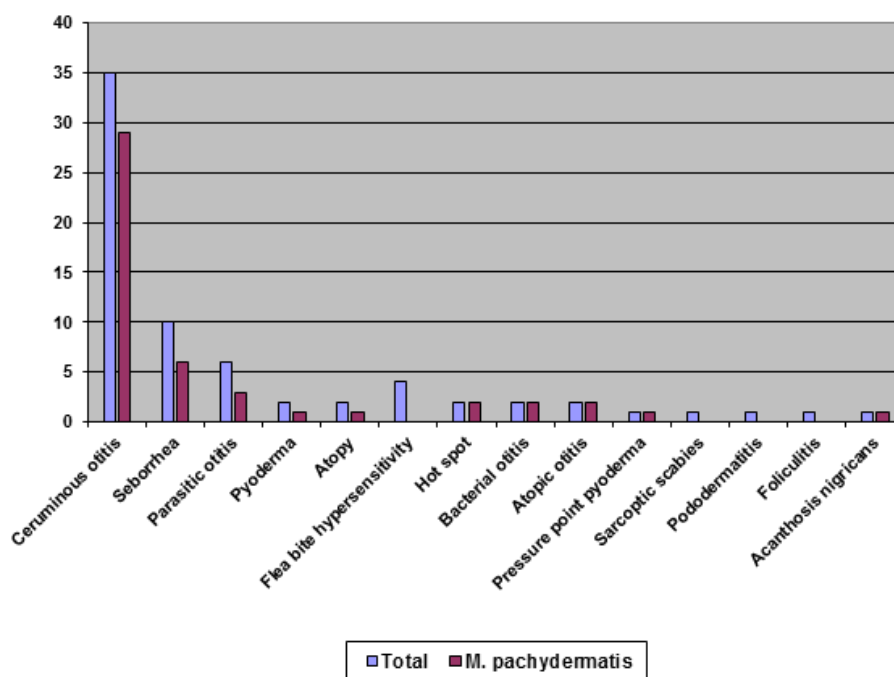


Figure 2. Distribution of *M. pachydermatis* isolates according to the diseases that predispose the development of the opportunist yeast.

Table 3. Distribution characteristics of 49 animals with *Malassezia pachydermatis* isolation associated with a skin disease or external otitis.

Disease	Isolation <i>M. pachydermatis</i>	Base disease (N)	Breed
Dermatopathies	13+	Seborrhea (6)	
		Skin fold pyoderma (2)	
		Atopy (2)	
		Flea bite hypersensitivity (4)	Mixed breed (MB)
		Hot spot (2)	Poodle
		Atopic otitis (2)	Daschund
		Pressure point pyoderma (1)	Cocker Spaniel English
		Sarcoptic scabies (1)	Sharpei
		Pododermatitis (1)	Labrador retriever
		Folliculitis (1)	German shepherd
		<i>Acanthosis nigricans</i> (1)	
		Folding dermatitis (2)	
		External otitis	36 +
Parasitic otitis (6)			
Bacterial otitis (2)			
Total	49	49	49

*No statistical difference between isolation of *M. pachydermatis* and gender, age or race.

described *M. pachydermatis* as a pathogenous opportunist which thrives in the medium where there is an increase in humidity and lipid cerumen composition, among other favorable factors (Amaral et al., 1998; Coutinho, 2005).

Cocker Spaniel English, Daschund and Poodle breeds showing dermatopathies, as well as animals of no definite breed, were the ones which presented the most dermatological problems, followed by Sharpei, Labrador, German Shepherd, Boxer and Bulldog breeds, though their sampling was not significant due to the few individuals available for each breed. In previous studies, Basset Hound, Boxer, Sharpei, Lhasa Apso, Cocker Spaniel English, Poodle, German Shepherd, Daschund, German Shepherd and Labrador retriever breeds have been described as being more dermatitis-prone (Nascente et al., 2004; Bond et al., 2002; Larsson et al., 1998). The breeds most often stricken by external otitis were Poodle, Cocker Spaniel English, Labrador retriever, Sharpei, Rotweiller, Old English Sheep Dog, Siberian Husky, Boxer, as well as those animals of no definite breed. According to Feijó et al. (1998), the breed most affected with otic infection by *Malassezia* is the Poodle. In external otitis cases, a greater percentage of animals with malasseziosis infection presented pendulum-like ears, such being the case of the Poodle and the Cocker Spaniel English. These findings were justified by Mansfield et al. (1990) as being the result of an alteration in the external ear canal microclimate. German Shepherd dogs have prick ears but are external otitis prone due to the apocrine glands (Guillot and Bond, 1999; Feijó et al., 1998). In our study, the Cocker

Spaniel English presented dermatitis and external otitis, in agreement with the findings by Larsson et al. (1998) and Feijó et al (1998), who consider this breed as being malasseziosis prone due to idiopathic seborrhea.

Age predisposition was not observed, once there was a wide age range among the studied animals was; these results are in agreement with those by Reynoud and Chauve (Reynaud and Chauve, 1984), who found equivalent percentages for animals in every age range. Feijó et al. (1998), though, found a great percentage of affected animals ranging from two months to three years of age, considering that young animals are more affected than adults.

Chengapa et al. (1983) also observed the disease caused by this yeast in every age range, but with a higher percentage in animals up to nine months. Other studies have reported a frequency in animals up to two years of age (Machado et al., 2003; Larsson et al., 1998). Choi et al. (2001) reported its occurrence in animals from one to three years of age and Dufait (1983) considered that most cases mostly occur in dogs older than two years.

In relation to sex, most of the animals referred to the Dermatological Clinic were male, in agreement with a study by Feijó et al. 1998. However, according to many authors (Coutinho et al., 2006; Girão et al., 2006; Larsson et al., 1998; Feijó et al., 1998; Mansfield et al., 1990), there is no sexual preference.

Conclusion

The results obtained confirms that the yeast may be a

strenuous and perpetuating factor for the diseases here reported. It is important to include chronic dermatitis and ceruminous otitis in the malasseziosis diagnosis protocol so that a better and faster resolution of the problem can be obtained, thus decreasing the risk of therapeutic failure, as well as avoiding the relapse of the disease.

Conflict of interests

The authors have not declared any conflict of interest.

REFERENCES

- Amaral R, Ibañez J, Mamizuka E, Walderez G, Paula CR, Larsson CE (1998) Microbiota indígena do meato acústico externo de gatos hígidos. *Ciência Rural* 28(1):441-445.
- Ashbee HR (2007) Update on the genus *Malassezia*. *Med. Mycol.* 45:287-303.
- Bond R, Curtis CF, Hendricks A, Ferguson EA, Lloyd DH (2002). Intra-dermal test reactivity to *Malassezia pachydermatis* in atopic dogs. *Vet. Rec.* 150:448-449.
- Bond R, Ferguson EA, Curtis F, Craig JM, Lloyd DH (1996). Factors associated with elevated cutaneous *Malassezia pachydermatis* populations in dogs with pruritic skin disease. *J. Small Anim. Pract.* 37:103-107.
- Bond R, Habibah A, Patterson-Kane JC, Lloyd DH (2006). Patch test responses to *Malassezia pachydermatis* in healthy dogs. *Med. Mycol.* 44:175-184.
- Chengapa M, Maddux R, Greer S (1983). A microbiologic survey of clinically normal and otitic canine ear canals. *Small Anim. Clin.* 34:3:1-3.
- Choi W, Lee S, Lee KW (2001). Aetiological and epidemiological features of canine dermatitis. *Korean J. Vet. Res.* 40:94-100.
- Coutinho SD, Fedullo JD, Corrêa SH (2006). Isolation of *Malassezia* spp. from cerumen of wild felids. *Med. Mycol.* 44:383-387.
- Coutinho SDA (2005). *Malassezia pachydermatis*: enzymes production in isolates from external ear canal of dogs with and without otitis. *Arq. Bras. Med. Vet. Zootec.* 57:149-153.
- Crespo MJ, Abarca ML, Cabañes FJ (2002). Occurrence of *Malassezia* spp. in the external ear canals of dogs and cats with and without otitis externa. *Med. Mycol.* 40:115-121.
- Dizotti CE, Coutinho SDA (2007). Isolation of *Malassezia pachydermatis* and *M. sympodialis* from the external ear canal of cats with and without otitis externa. *Acta Vet. Hung.* 55:471-477.
- Dufait R (1983). *Pityrosporum canis* as the cause of canine chronic dermatitis. *Vet. Med. Small Anim. Clin.* 78:1055-1057.
- Dworecka-Kaszak B, Szykiewicz Z, Blaszcak B (1994). Evaluation of selected physiological and morphological characteristics of *Pityrosporum pachydermatis* isolated from clinical cases of otitis externa and dermatitis in dogs and cats. *Arch. Vet. Pol.* 34:163-175.
- Feigl M, Mós E, Larsson C, Santos M (1981). Estudo microbiológico das otites externas em cães. *Braz. J. Microbiol.* 12:88-91.
- Feijó F, Campos S, Ramadina R (1998). Epidemiologia da otite por *Malassezia pachydermatis* em cães. *Rev. Bras. Med. Vet.* 2:197-200.
- Gabal MA (1988). Preliminary studies on the mechanism of infection and characterization of *Malassezia pachydermatis* in association with canine otitis externa. *Mycopathology* 104:93-98.
- Gentilini E, Denamiel G, Escalada J, Neyra J (1991). Otitis canina cronica hallazgos microbiológicos y sensibilidad a los antibióticos. *Vet. Arg.* 8:113-117.
- Girão MD, Prado MR, Brilhante RS, Cordeiro RA, Monteiro AJ, Sidrim JJ, Rocha MF (2006). *Malassezia pachydermatis* isolated from normal and diseased external ear canals in dogs: a comparative analysis. *Vet. J.* 172:544-548.
- Guého E, Midgley G, Guillot J (1996). The genus *Malassezia* with description of four new species. *Antonie van Leeuwenhoek* 69:337-355.
- Guillot J, Bond R (1999). *Malassezia pachydermatis*: A review. *Med. Mycol.* 37:295-306.
- Kindo AJ, Sophia SK, Kalyani J, Anandan S (2004). Identification of *Malassezia* species. *Indian J. Med. Microbiol.* 22:179-181.
- Kiss G, Radványi S, Szigeti G (1997). New combination for the therapy of canine otitis externa. I. Microbiology of otitis externa. *J. Small Anim. Pract.* 38:51-56.
- Larsson CE, Larsson MH, Amaral R (1988). Dermatitis in dogs caused by *Malassezia (Pityrosporum) pachydermatis*. *Vet. Arch.* 4:63-68.
- Leite CAL, Abreu VLV, Costa GM (2003). Frequência de *Malassezia pachydermatis* em otite externa de cães. *Arq. Bras. Med. Vet. Zootec.* 55:102-104.
- Machado ML, Appelt C, Ferreira L, Guillot J (2003). Otites e dermatites por *Malassezia* spp. em cães e gatos. *Clín. Vet.* 44:27-33.
- Mansfield P, Boosinger T, Attleberger M (1990). Infectivity of *Malassezia pachydermatis* in the external ear canal of dogs. *J. Am. Anim. Hosp. Assoc.* 26:97-100.
- Mariat F, Adan-Campos C (1967). La technique du carré de tapis methode simples de prelevement dans les mycoses superficiales. *Ann. Inst. Pasteur.* 113:666-668.
- Nagata M (2013) *Malassezia* and its presumed association with skin diseases in dogs. *Med. Mycol. J.* 54:45-47.
- Nardoni S, Dini M, Taccini F, Mancianti F (2007). Occurrence, distribution and population size of *Malassezia pachydermatis* on skin and mucosae of atopic dogs. *Vet. Microbiol.* 122:172-177.
- Nardoni S, Mancianti F, Rum A, Corazza M (2005). Isolation of *Malassezia* species from healthy cats and cats with otitis. *J. Feline Med. Surg.* 7:141-145.
- Nascente PN, Nobre MO, Meinerz AR, Gomes FR, Souza LL, Meireles MCA (2004). Ocorrência de *Malassezia pachydermatis* em cães e gatos. *Rev. Bras. Med. Vet.* 26:79-82.
- Prado MR, Brito EH, Brilhante RS, Cordeiro RA, Leite JJ, Sidrim JJ, Rocha MF (2008). Subculture on potato dextrose agar as a complement to the broth microdilution assay for *Malassezia pachydermatis*. *J. Microbiol. Methods* 75:341-343.
- Reynaud M, Chauve E (1984). *Pityrosporum canis*: observation cliniques et contribution a l'etude systeme enzymatique des souches isolées. *Annales Société Française Médicine Vétérinaire* 1:210-212.