

Case Report

# A rare disease process with deadly consequences and a therapeutic dilemma – spontaneous coronary artery dissection: A literature review

Sunil Naik\*, Nicholas Tisdale, Nadir Rehman and Shukri David

Department of Cardiology, Providence Hospital and Medical Centers, 16001 W. Nine Mile Road  
Southfield, MI. 48075, USA.

Received 17 February, 2013; Accepted 18 June, 2013

**Spontaneous coronary artery dissection is a rare but deadly disease process that continues to have an elusive pathophysiology and treatment strategy. We present a 32 year old patient who suffered from a spontaneous dissection of the left anterior descending artery. Multiple case reviews in the literature were reviewed, but no randomized controlled trials are available to help guide our therapy. A conservative strategy was chosen until her pain recurred and a second-look angiogram was performed. Coronary dissection progressed to the circumflex system and severe ventricular dysfunction was noted. The patient recovered well from coronary artery bypass grafting and was discharged in stable condition. This report reviews the proposed pathophysiology and summarizes the literature in terms of appropriate management of these patients.**

**Key words:** Spontaneous coronary artery, patient, dissection.

## INTRODUCTION

Spontaneous coronary artery dissection is rare, but it is recognized throughout the cardiology community as a potentially life threatening disease. Despite 450 to 500 reported cases over the past 50 years, it has been difficult to compare various treatment modalities to establish universal guidelines for therapy. Many of the cases reviewed over the last 50 years used medical therapy and bypass as therapeutic options. Now, the advancements in percutaneous coronary interventions (PCI) have changed the potential treatments that can be offered and may be beneficial in this population of young and otherwise healthy patients. The clinical dilemma in this case involves which intervention is most appropriate despite a lack of evidence to guide therapy. The

underlying mechanism also remains a clinical mystery with theories of pathophysiology, but there is no true understanding of why this disease process occurs.

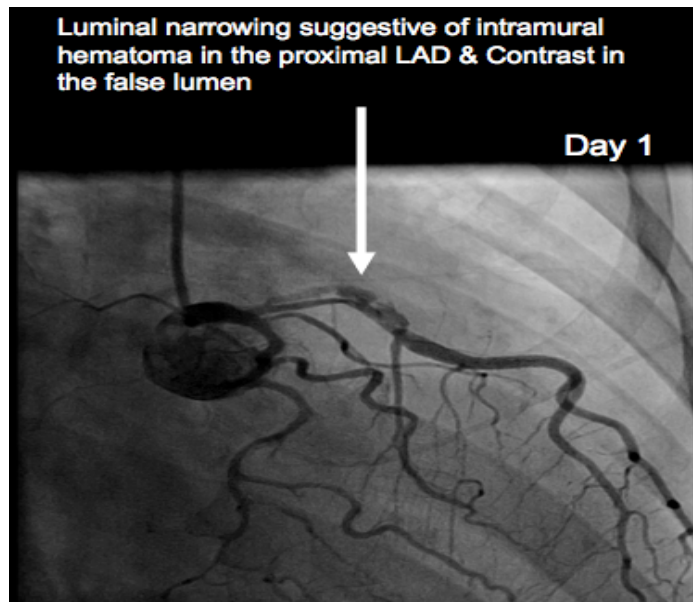
## CASE REPORT

A 32 year old G4P2 African American female, with a history of hyperthyroidism on propylthiouracil (PTU) gave birth to a healthy baby boy, 3 weeks prior to presenting with acute onset of substernal chest pressure radiating towards the upper back. The pain continued for about 40 min and was associated with diaphoresis, nausea and vomiting. The patient denies a history of pulmonary embolism, deep venous thrombosis, or previous coronary artery disease.

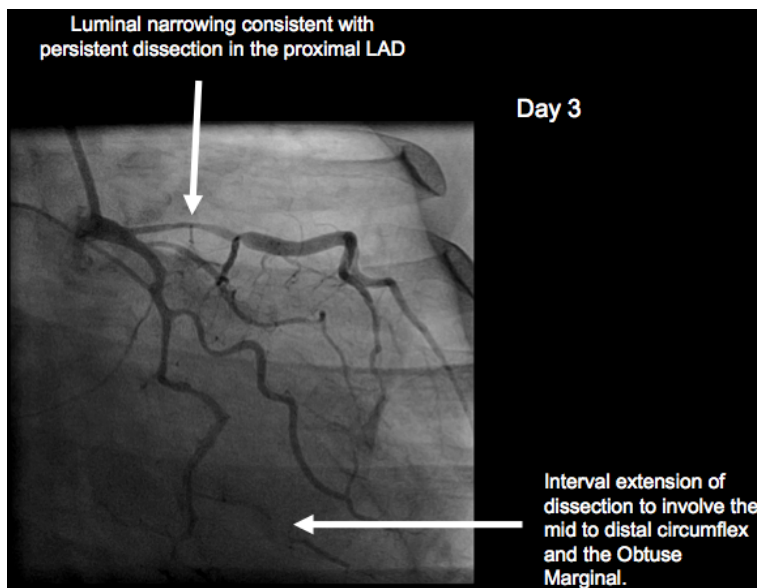
Patient history included tobacco abuse and occasional alcohol

\*Corresponding author. E-mail: [naiks07@gmail.com](mailto:naiks07@gmail.com). Tel: 281 546 5043. Fax: 248 849 3151.

Author(s) agree that this article remain permanently open access under the terms of the [Creative Commons Attribution License 4.0 International License](http://creativecommons.org/licenses/by/4.0/)



**Figure 1.** Coronary artery dissection with intraluminal narrowing of the proximal LAD. Contrast staining of the thrombus in the false lumen.



**Figure 2.** Luminal narrowing of the proximal LAD and progression of dissection involving the distal LCX and OM branch.

usage. Upon arriving at the cardiovascular intensive care unit (CVICU), she was started on heparin, aspirin, statin and beta-blockers. The physical exam revealed normal vital signs and no significant abnormalities on cardiovascular and respiratory physical examination. Laboratory data was significant for elevated troponin T of 0.28 and creatinine of 1.7.

Electrocardiography (ECG) showed sinus bradycardia at a rate of 58 beats per minute with left posterior fascicular block and biphasic

T wave changes in the anterolateral distribution. The diagnosis of a non-STEMI was confirmed. The next day, she underwent cardiac catheterization and a proximal left anterior descending artery dissection was found (Figures 1 and 2). She had preserved left ventricular function and was hemodynamically stable, thus she was treated with medical therapy and close observation in the CVICU. The patient did well for over 24 h on medical therapy with aspirin, prasugrel, lopressor, prinvil, and simvastatin. On the 3rd day, she

developed recurrence of similar chest pain as described on admission.

Repeated cardiac catheterization revealed progression of the coronary dissection into the proximal LAD/left main and the circumflex arteries (Figure 2). The left ventricular function was severely impaired with an ejection fraction (EF) of 25%. Due to ongoing chest pain and new development of impaired left ventricular (LV) function, the patient was then sent for urgent coronary artery bypass grafting. The operative procedure included an internal mammary artery to the left anterior descending (LAD) and a saphenous vein graft to the obtuse marginal branch. The patient had a successful recovery with no postoperative complications and was discharged in stable condition.

## DISCUSSION

Spontaneous coronary artery dissection (SCAD) is an infrequent cause of acute coronary syndrome, but is likely under diagnosed secondary to sudden cardiac death before presentation. A case of SCAD tends to be quite difficult to treat simply because the natural history and pathophysiology of this condition remain elusive. We present a case of SCAD and review the literature in attempts to summarize available information about the natural history of the disease and to develop a systematic approach to treatment options.

SCAD has been noted to be associated with prolonged chest trauma, severe hypertension, smoking, strenuous activity and illicit drug use (Glamore et al., 2012; Hoyer, 2010; McCann and Whibourn, 2009). Dissection generally occurs in the outer tunica media or in between the media and external elastic lamina (McCann and Whibourn, 2009). Approximately one third of women with SCAD are pregnant or postpartum (Glamore et al., 2012; McCann and Whibourn, 2009). There are a few prevailing mechanisms that attempt to explain the pathology of SCAD in the peripartum period. Elevated estrogen levels lead to smooth muscle hypertrophy, decrease acid mucopolysaccharides and decreased collagen which all lead to weakened arterial wall architecture. During times of increased cardiac output and wall stresses such as pregnancy, the milieu for vaso vasorum rupture is prevalent (Hoyer et al., 2010). Another hypothesis involves protease-secreting eosinophils that result in a lytic action of proteins in the vessel wall. Post mortem studies of SCAD patients have found elevated eosinophil to lymphocyte ratios and may indicate a mechanism of weakened arterial wall integrity. These hormonal and volume changes usually resolve 3 months after pregnancy. This correlates well with a dramatic decrease in the number of SCAD related to pregnancy after this time period. Without a consensus on the true etiology of this disease, the management for it remains a great challenge.

Making the diagnosis requires a high index of suspicion. Young females in the peripartum period can present similarly with peripartum cardiomyopathy, pulmonary embolism, aortic dissection, or rarely coronary

artery disease. Many of these conditions can be evaluated with CT angiography or echocardiography. When SCAD is suspected and objective evidence of acute coronary syndrome is present, proceeding with coronary angiography is reasonable. There are no distinct guidelines for this particular condition, but angiography provides a means of diagnosis and treatment. Also, techniques such as intravascular ultrasound (IVUS) and optical coherence tomography (OCT) give a perspective of intramural involvement and vaso vasorum rupture. These innovative imaging modalities have been used successfully in the diagnosis of SCAD (Poon et al., 2011). However, the risks involved with passing these devices through vulnerable vessels with dissection may result in complications and has not been well studied.

One of the toughest tasks in treating SCAD is the controversy over which therapeutic modality should be employed. Over the past 50 years, there have only been about 500 reported cases of SCAD (Tanis et al., 2008; Shamloo et al., 2010). However, developing evidence based guidelines has been difficult with only selected case reports and no randomized trials. During this time, the advances in medical therapy, bypass surgery and percutaneous interventions have made generalizations about treating this condition even more challenging.

Medical therapy with aspirin, clopidogrel, beta blockers, angiotensin-converting-enzyme (ACE) inhibitors and statins, have to be used with caution in this selected group of pregnant or breast feeding patients. An innovative option is the use of immunosuppressants, which evolved from the hypothesis of increased eosinophil and protease activity. This has been studied and found to have benefit in a paper by Koller et al. (1998). The use of thrombolytics was noted many years ago in the data but found to have worse outcomes in SCAD based on anecdotal evidence and is no longer in favor (Koul et al., 2001).

The next therapeutic dilemma is percutaneous intervention (PCI) versus bypass grafting. Both options have been used in many of the case reports and reviews of the literature, but no data has shown superiority of either strategy. After looking at the details of these cases, there are some important considerations that need to be made about both modalities. PCI seems to be a viable and successful strategy in cases of ongoing ischemia in a single vessel territory that does not involve the left main coronary artery. Particular challenges with this modality include wiring the true lumen, compromising side branches and confirming that the entire dissection is covered. These issues must be considered when choosing PCI as the treatment modality for a successful result. Coronary artery bypass grafting (CABG) has shown good outcomes in these cases especially with multiple vessel involvement or failed PCI. However, considerations such as cardiopulmonary bypass in a pregnant patient, fetal outcomes, and graft closure should be addressed prior to choosing this approach.

Finally, some patients have done well with medical therapy and observation alone. Spontaneous healing of these dissections is possible; however, the data suggests that this should not be the primary strategy. The literature shows that 30 to 40% of patients who were followed from a medical therapy approach required intervention within 2 months of their acute event (Tanis et al., 2008). There is not enough information to assess the effects that this had on long-term survival or LV function.

### Conclusion

In the coming future, the hopes of developing a fundamental set of guidelines for the treatment of SCAD are very promising. In particular, the discovery study is a prospective multicenter registry with case control, which will work to further elucidate the role of SCAD in the pathogenesis of acute coronary syndromes (Fontanelli et al., 2009). This ongoing trial will work to evaluate coronary dissections in Europe and provide essential information regarding the most beneficial treatments for SCAD.

### Conflict of interest

No competing interests were disclosed.

### REFERENCES

- Fontanelli A, Olivari Z, La Vecchia L, Basso C, Pagliani L, Marzocchi A, Zonin P, Vassanelli C, Di Pede F (2009). Spontaneous dissections of coronary arteries and acute coronary syndromes: rationale and design of the DISCOVERY, a multicenter prospective registry with a case-control group. *J. Cardiovasc. Med.* 10:94-9.
- Glamore MJ, Garcia-Covarrubias L, Harrison LH Jr, Moreno NL (2012). Spontaneous Coronary Artery Dissection. *J. Card. Surg.* 27:56-9.
- Hoye A (2010). Spontaneous Coronary Artery Dissection: Time for a concerted effort to better understand this rare condition. *J. Invasive Cardiol.* 22(5):229-30.
- Koller PT, Cliffe CM, Ridley DJ (1998). Immunosuppressive therapy for peripartum type spontaneous coronary artery dissection; case report and review. *Clin. Cardiol.* 21(1):40-6.
- Koul AK, Hollander G, Moskovits N, Frankel R, Herrera L, Shani J (2001). Coronary artery dissection during pregnancy and the postpartum period: two case reports and review of literature. *Catheter Cardiovasc. Interv.* 52:88-94.
- McCann A, Whibourn R (2009). Spontaneous coronary artery dissection: a review of the etiology and available treatment options. *Heart Vessels* 24:463-5.
- Poon K, Bell B, Raffel OC, Walters DL, Jang IK (2011). Spontaneous Coronary Artery Dissection: Utility of Intravascular Ultrasound and Optical Coherence Tomography During Percutaneous Coronary Intervention. *Circ. Cardiovasc. Interv.* 4:e5-e7.
- Shamloo BK, Chintala RS, Nasur A, Ghazvini M, Shariat P, Diggs JA, Singh SN (2010). Spontaneous coronary artery dissection: aggressive vs. conservative therapy. *J. Invasive Cardiol.* 22(5):222-8.
- Tanis W, Stella PR, Kirkels JH, Pijlman AH, Peters RHJ, de Man FH (2008). Spontaneous coronary artery dissection: current insights and therapies. *Neth. Heart J.* 16:344-9.