

## Short Communication

# Lymphoma presenting as non-responding cellulitis

Ali Akbar Heydari\*, Mohammad Reza Sarvghad, Naser Tayebi meybodi, Hosain Safari, Elena Saremi and Valiollah Booriazadeh

Imam Reza Hospital, Mashad, Iran

Accepted 9 January, 2013

**We report a case of primary lymphoma in a 66-year-old woman who presented with unresponsive cellulitis. Histopathological sections carried out on the woman revealed a non-Hodgkin's lymphoma. Atypical physical findings of cellulitis such as fibrotic and woody induration may be suggestive of a non-infectious disease.**

**Key words:** Lymphoma, cellulitis, refractory infection

## INTRODUCTION

Muscle involvement of lymphoma is uncommon, comprising 0.5% of extranodal non-Hodgkin's lymphoma (NHL), and some lymphomas might cause compartment syndrome since they involve muscle (Laura et al., 2011; Chim et al., 1999; Southworth et al., 1990). Non-Hodgkin lymphomas and Hodgkin disease can present with dermatologic manifestations. Sometimes, lymphoma presents as cellulitis and is diagnosed after failure of antibiotic therapy (Falagas and Vergidis, 2005). This study reports a case of T-cell lymphoma with diffuse skin and soft-tissue changes which is suggestive of cellulitis.

## CASE REPORT

A 66-year-old woman presented with a 20 days history of left arm swelling and hardness, without fever or chills. A broad-spectrum intravenous antibiotic had been prescribed for one week in a previous hospital; being without any significant remission, the patient was referred with a diagnosis of refractory cellulitis. Her chief complaints at the time of presentation were pain, edema and redness of her left arm. She was admitted to Imam Reza Hospital with a diagnosis of cellulitis. At the time of admission, the patient's vital signs were as follows: axillary temperature of 37.3°C; pulse rate of 120 beats/min; respiratory rate of 30 beats/min; and blood pressure of 190/80 mmHg. Physical examination revealed erythema and tenderness on her left arm (Figure 1). Laboratory was normal, abdominal computerized tomography (CT) scan revealed no

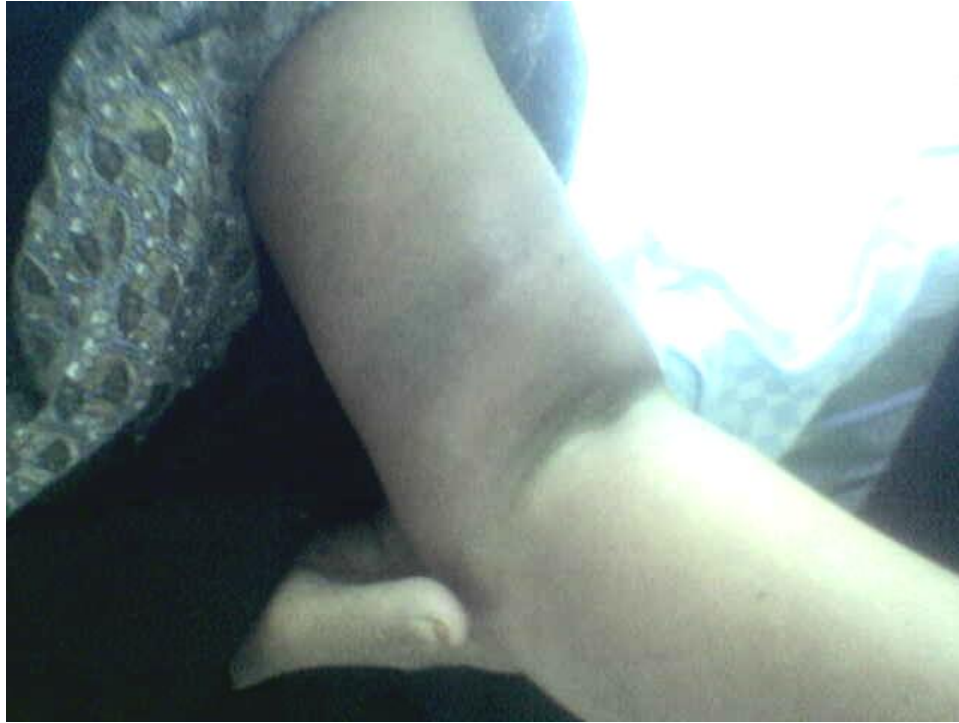lymphadenopathy and no splenomegaly, and sonography of the muscle mass of the anterior compartment of the left arm showed several hypo echo centers (5 to 7 mm). The diagnosis was established on the basis of histopathologic examination and immunohistochemical studies. A biopsy of the arm lesion was performed. Histologic sections (Figure 2) revealed diffuse infiltrate of pleomorphic lymphoid cells with vast necrosis compatible with non-Hodgkin's lymphoma extending throughout the entire dermis into the subcutaneous fat and muscle. The immunohistochemical staining (ABC method) for leukocyte common antigen (LCA), CD30, and CD45RO were positive and there was a negative result for CD20. The patient was referred to the hematology-oncology for evaluation and treatment.

## DISCUSSION

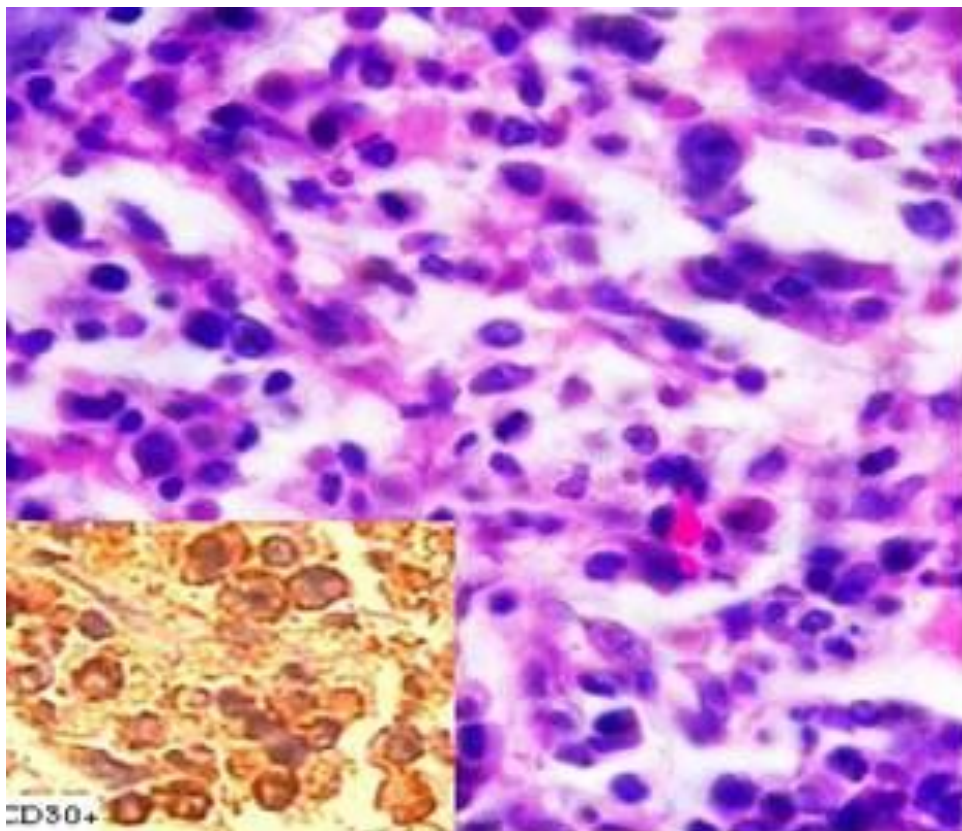
The patient in this study was presented with suspected cellulitis that did not respond to conventional antimicrobial treatment; hence, one should consider, among other explanations, several noninfectious disorders that might masquerade as infectious cellulitis. These noninfectious disease include thrombophlebitis, contact dermatitis, insect stings, drug reactions, eosinophilic cellulitis, carcinoma erysipeloides, familial Mediterranean fever, foreign-body reactions, urticaria, lymphedema, lupus erythematosus, sarcoidosis, lymphoma, leukemia, Paget disease, and panniculitis (Falagas and Vergidis, 2005).

Almost any organ can be affected by lymphoma, with the most common extranodal sites of involvement being the stomach, spleen, Waldeyer ring, central nervous system, lung, bone, and skin (Paes et al., 2010).

\*Corresponding author. E-mail: HeydariAA@mums.ac.ir.



**Figure 1.** Edema and erythema of the patient's left arm.



**Figure 2.** ALCL diffuse infiltration of pleomorphic lymphoid cells (H&E, X100). \*Avidine-biotin-peroxidase complex method

Anaplastic large cell lymphoma (ALCL) of the primary cutaneous type is defined in the World Health Organization (WHO) classification as an ALCL presenting in the skin in patients with no pre-existing lymphoproliferative disease and no evidence of extra-cutaneous disease at the time of diagnosis. Primary cutaneous ALCL is a neoplasm of large lymphoid cell with large, often pleomorphic nuclei and abundant cytoplasm. These tumors have been referred to as large cell anaplastic (Ki-1+) lymphomas by virtue of their expression of the CD30 antigen (Beljaards et al., 1993).

Primary cutaneous ALCL affects predominantly older adults and is rare in children. Most cases show limited disease with solitary or localized skin tumors or nodules. The prognosis is favorable, with long-term remissions or even spontaneous regressions. Systemic disease develops in approximately 25% of the patients. Based upon the histological workup, our patients tumor appears to represent one end of a biological spectrum, known as "CD30+ cutaneous lymphoproliferative disease", which includes lymphomatoid papulosis at the clinically benign end and primary cutaneous ALCL at the malignant end (de Bruin et al., 1993; Kaudewitz et al., 1989).

## Conclusion

Lymphoma should be considered as a cause of refractory cellulitis and isolated enlarged skeletal muscles. Atypical physical findings such as fibrotic and woody induration should suggest other diagnosis such as lymphoma and other non-infectious diseases.

## REFERENCES

- Beljaards RC, Kaudewitz P, Berti E, Gianotti R, Neumann C, Rosso R, Paulli M, Meijer CJ, Willemze R (1993). Primary cutaneous CD30-positive large cell lymphoma: definition of a new type of cutaneous lymphoma with a favorable prognosis. A European Multicenter Study of 47 patients. *Cancer* 71(6):2097-2104.
- Chim CS, Choy C, Liang R (1999). Primary anaplastic large cell lymphoma of skeletal muscle presenting with compartment syndrome. *Leuk. Lymphoma* 33(5-6):601-605.
- de Bruin PC, Beljaards RC, van Heerde P, Van Der Valk P, Noorduyt LA, Van Krieken JH, Kluin-Nelemans JC, Willemze R, Meijer CJ (1993). Differences in clinical behaviour and immunophenotype between primary cutaneous and primary nodal anaplastic large cell lymphoma of T-cell or null cell phenotype. *Histopathology* 23(2):127-135.
- Falagas ME, Vergidis PI (2005). Narrative review: Diseases that masquerade as infectious cellulitis. *Ann. Intern. Med.* 142(1):47-55.
- Kaudewitz P, Stein H, Dallenbach F, Eckert F, Bieber K, Burg G, Braun-Falco O (1989). Primary and secondary cutaneous Ki-1+ (CD30+) anaplastic large cell lymphomas. Morphologic, immunohistologic, and clinical-characteristics. *Am. J. Pathol.* 135(2):359-367.
- Laura B, Rashmi M, George S (2011). Diffuse large B-Cell lymphoma with calf muscle localization. *Case Report. Hematol.* 2011:292494. doi: 10.1155/2011/292494.
- Paes FM, Kalkanis DG, Sideras PA, Serafini AN (2010). FDG PET/CT of extranodal involvement in non-Hodgkin lymphoma and Hodgkin disease. *Radiographics* 30(1):269-291.
- Southworth SR, O'Malley NP, Ebraheim NA, Zeff L, Cummings V (1990). Compartment syndrome as a presentation of non-Hodgkin's lymphoma. *J. Orthop. Trauma* 4(4):470-473.