

*Full Length Research Paper*

# Expression of protein-gene peptide (PGP) 9.5 in myocardial sleeves around the pulmonary artery and aorta in pigs

Jingping Lu, Dongsheng Zhao, Gang Zhang, Jie Gen and Qijun Shan\*

Department of Cardiology, First Affiliated Hospital of Nanjing Medical University, 300 Guangzhou Road, Nanjing, 210029, Jiangsu Province, China.

Accepted 23 July, 2012

**A subgroup of outflow tract (OT) ventricular tachycardias (VT) originates from the aortic sinuses or the main stem of the pulmonary artery. Myocardial sleeves onto the pulmonary artery (PA) and aorta (Ao) have been recognized as a frequent site for the origin of arrhythmia. The aim of this study was to analyze PGP9.5 expression in pulmonary artery and aorta from 100 pigs hearts and relate it to the mechanism of arrhythmia. The pulmonary artery and aorta were obtained from 100 healthy pigs; longitudinal strips of tissue containing each cusp, aortic, pulmonary artery walls, left and right ventricular outflow tracts were excised and histologically analyzed. PGP9.5 was studied immunohistochemically in myocardial sleeves. Myocardial sleeves were found in 88 of 100 AOs (88%) and 20 of 100 PAs (20%). PGP9.5 positivity was observed in 89 of 90 (99%) pigs, which had myocardial sleeves. PGP9.5 immunopositivity can be detected in most pig myocardial sleeves around the PAs and AOs; this finding may contribute to the substrate for OT VTs.**

**Key words:** Myocardial sleeves, ventricular tachycardia, aortic sinus, pulmonary artery, protein-gene peptide (PGP) 9.5.

## INTRODUCTION

Ventricular tachycardia arising from the right or left ventricular outflow tract is a recognized arrhythmia in individuals with structurally normal hearts. The left and right outflow tracts share a common embryonic origin, which explains the similarity of the tachycardias (Lerman et al., 1996, 1997; Stevenson, 2005; Iwai et al., 2006; Bunch and Day, 2006). It has recently been shown that a subgroup of outflow tract ventricular tachycardias (OT VTs) originated from the aortic sinuses or the main stem of the pulmonary artery (Shimoike et al., 1999; Ouyang et al., 2002; Sadanaga et al., 1999; Tada et al., 2004; Kanagaratnam et al., 2001).

A lot of studies have shown atrial myocardium extends into the pulmonary and caval veins plays a critical role in the initiation of atrial fibrillation (AF) (Haissaguerre et al., 1998; Tsai et al., 2000; Mansour et al., 2002). Ventricular

myocardial extensions onto the pulmonary artery (PA) and aorta (Ao) beyond the ventriculo-arterial junction are relatively common. It seems that their mere presence does not predispose to OT VTs. There are probably intrinsic arrhythmia properties in tissues specific to these regions in those patients who develop OT VTs (Hasdemir et al., 2007). The precise mechanism of these ventricular myocardial sleeves and their role in the causation of arrhythmia need to be explored further.

PGP9.5 is a new cytoplasmic neuron-specific protein structurally and immunologically distinct from neuron-specific enolase. Interestingly, PGP9.5 immunoreactivity has been described in morphologically dynamic myocardial regions during heart ontogenesis that may subsequently play a role in triggering arrhythmia. Expression of PGP9.5 has also been hypothesized to correspond with abnormal ventricular automaticity. In addition, some authors used PGP9.5 as a marker of the conduction system (El et al., 2001; Crick et al., 1999a, 1996). The aim of this study therefore was to analyze PGP9.5 expression in pulmonary artery and aorta from

\*Corresponding author: E-mail: [qjshan@njmu.edu.cn](mailto:qjshan@njmu.edu.cn). Tel: +86-25-868136407.

100 pig hearts and relate it to the mechanism of arrhythmia.

## MATERIALS AND METHODS

### Anatomy

A hundred adult Chinese mongrel pigs of either sex weighing about 90 kg were used in this study. In all subjects, the heart was excised together with PA and Ao. The ascending AOs and PAs were transected at the pericardial reflections. The aortic and pulmonary roots were opened by longitudinal incisions through the left aortic cusp and the anterior pulmonary cusp. The original strips of tissue samples were cut into three equal-sized pieces, containing each cusp, aortic and PA walls 20 mm above the ventriculo-arterial junction (VAJ), and left and right ventricular myocardial 20 mm below the VAJ, these were then fixed with 10% formalin.

### Histology

Specimens were routinely dehydrated and embedded in paraffin using an automatic tissue processor. Serial sections were cut at 4 to 5  $\mu\text{m}$  thickness and mounted on poly L-lysine prepared slides. Serial sections were stained with haematoxylin and eosin (H & E) stain. The presence of myocardial sleeves was evaluated in each section microscopically.

### Immunohistochemistry

Immunohistochemistry was performed with antibodies against Protein gene peptide 9.5 (PGP 9.5, rabbit polyclonal, dilution 1:200, abcam). Deparaffinized sections were rehydrated and immunostained according to the following protocol: endogenous peroxidase activity was inhibited, 30 min incubation in 0.3% hydrogen peroxide and methanol followed by tap water wash, the slides were incubated in a retrieval solution for 15 min at 95°C, which was cooled in the solution naturally and then washed in PBS (Phosphate Buffered Saline) 3 times, 3 min each. Subsequently, the sections were blocked with blocking buffer (from Boster, SA1022) and incubated for 20 min at room temperature in a humidified chamber and finally with avidin biotin peroxidase complex (Vectastain ABC kit, CA, USA) for 1 h. Peroxidase activity was detected by incubation of the slides with diaminobenzidine tetrahydrochloride (DAB) and  $\text{H}_2\text{O}_2$  for 5 min. After washing with distilled water, sections were counterstained with haemalum, dehydrated and mounted with DPX. For negative controls, the first antibody was replaced by PBS. Staining intensity was evaluated as negative (-), faintly positive (+), moderately positive (++) and strongly positive (+++).

## RESULTS

### Morphological characteristics

Myocardial sleeves were found in 90 of 100 (90%) pigs studied. Ventricular myocardial extensions beyond the ventriculo-arterial junction were found in 108 of 200 (54%) of the great arteries examined. 18 pigs had both aortic and pulmonary myocardial sleeves. Myocardial sleeves were continuous in 70 (78%), discontinuous in 13 (14%), and both in 7 (8%). Myocardial sleeves were oriented obliquely in 16 (18%) and longitudinally in

20 (22%), and both in 54 (22%). Myocellular hypertrophy and fibrosis were present in 69 (77%) and fatty tissue between the myocardial sleeve was 63 (70%).

Myocardial sleeves were found in 88 of 100 AOs examined (88%): 71 around the right coronary sinus, 15 around the left coronary sinus, and 59 around the noncoronary sinus (Figure 1).

Myocardial sleeves were found in 20 of 100 PAs examined (20%). Myocardial sleeves in the PAs were located in the anterior pulmonary sinus in 9, in the left pulmonary sinus in 12 and in the right pulmonary sinus in 1 (Figure 2).

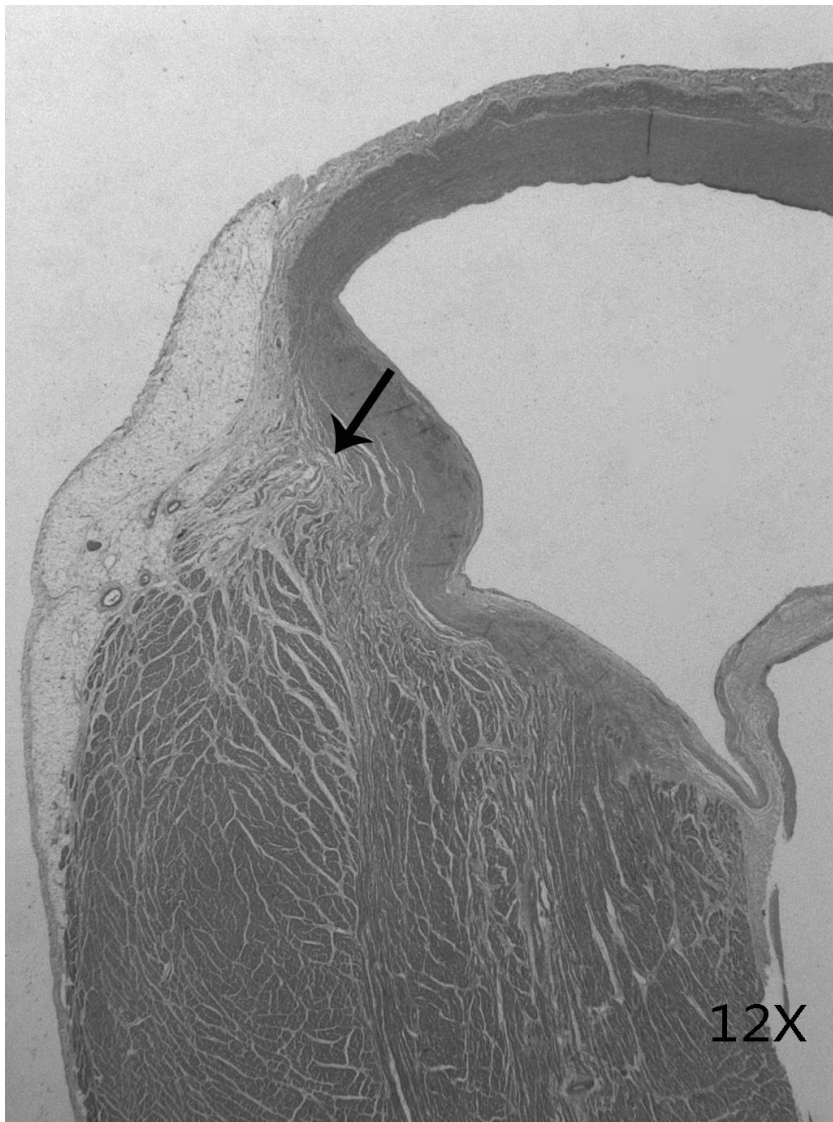
### Expression of protein-gene peptide (PGP) 9.5

PGP9.5 positivity was observed in 89 of 90 (99%) pigs, which had myocardial sleeves (Figure 3). PGP9.5 negative was found in 5 of 59 (8%) in noncoronary sinus, 4 of 71 (6%) in right coronary sinus, 1 of 9 (1%) in anterior pulmonary sinus.

## DISCUSSION

Ventricular tachycardia has diverse mechanisms and sites of origin. Most VT originate from ventricular myocardium, however, a subgroup of OT VTs originates from the aortic sinuses or the main stem of the PA (Sadanaga et al., 1999; Sekiguchi et al., 2005; Hachiya et al., 2002). VT originating above the level of the semilunar valves has also been described in a small number of case studies. Our study has shown that ventricular myocardial extensions extend into the aorta and pulmonary artery beyond the semilunar valves. Ventricular myocardium extending into the great vessels above the semilunar valves may be a trigger for the arrhythmia, similar to that observed from the superior vena cava and pulmonary veins in patients with atrial fibrillation (Haissaguerre et al., 1998; Tsai et al., 2000; Mansour et al., 2002). Nevertheless, in some cases, these potentials may result from bystander tissue to getting passively activated from the ventricle. The precise mechanism of these potentials and their role in the causation of arrhythmia need to be explored further.

PGP9.5 was expressed by cardiac nerves and conducting system components, and successfully used to quantify the innervation of the conducting system of the adult calf, pig, guinea pig and human heart. It serves as useful markers for the cardiac conducting system (Crick et al., 1996, 1999a, 1999b). The sinus node, atrioventricular node, atrioventricular bundle and both left and right bundle branches all possessed a significantly higher density of PGP9.5-immunoreactive nerves relative to their surrounding myocardial tissues (El et al., 2001). PGP9.5 immunopositivity has been hypothesized to be associated with abnormal automaticity in human embryos, suggesting that this parameter could be used to

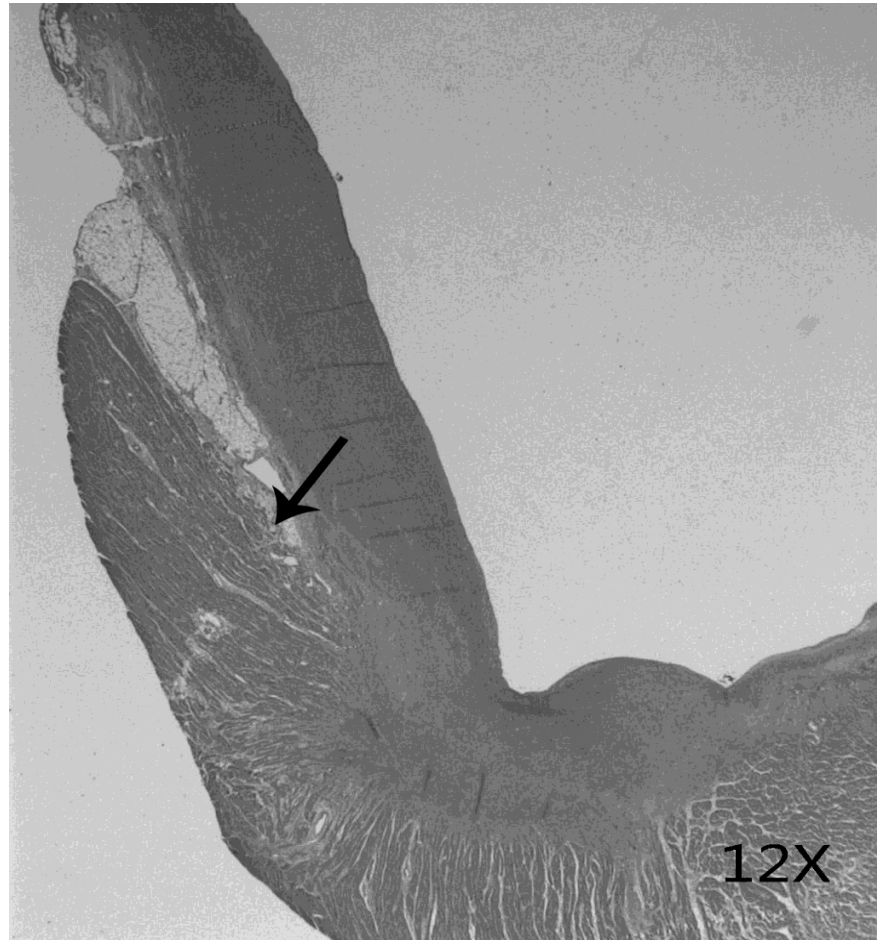


**Figure 1.** Long axis view of the pulmonary root, stained with HE stain, myocardial sleeves is shown by the arrow.

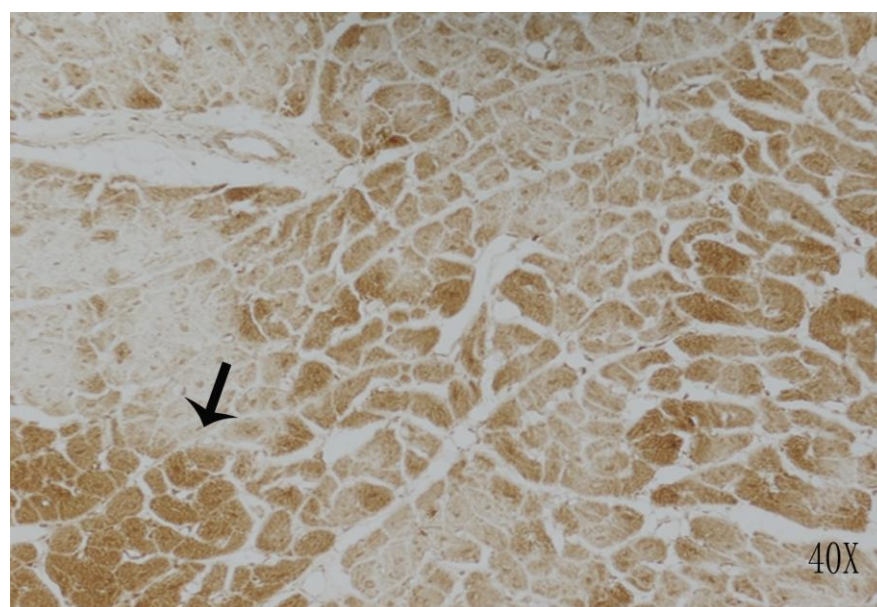
identify foci with a potential for abnormal automaticity in ventricular myocardium. These findings indicate that a nonreentrant mechanism of VT, like automaticity or triggered activity, would be an explanation for the mechanism responsible for the VT in this study.

However, OT VTs that are based on a reentrant mechanism have been reported. The other hypothesis may reflect the fact that myocardial sleeves corresponding with PGP9.5 intensity may be a bystander tissue getting passively activated from the ventricle. Rich PGP9.5 positive innervation of all the components of the conduction tissues displayed a homogeneous distribution. In this respect, the presence of regions that possessed a high density of PGP 9.5-immunoreactive nerve trunks and fibres in the myocardial sleeves

extending into the aorta and pulmonary artery beyond the semilunar valves, may provide some evidence for the existence of 'preferential conduction pathways' through the atrioventricular nodal region. The true relationship of these 'nerve pathways' to the preferential conduction routes into the node is, however, highly controversial and merits further investigation. Ventricular myocardial extensions extending into the aorta and pulmonary artery in pigs are relatively common. Although PGP9.5 immunopositivity can be detected in some myocardial sleeves, this finding does not appear to reflect the prevalence of arrhythmogenic foci in OT VTs. The precise mechanism of these myocardial sleeves and their role in the causation of arrhythmia need to be explored further.



**Figure 2.** Long axis view of the aortic root, stained with HE stain, myocardial sleeves is shown by the arrow.



**Figure 3.** Myocardial sleeves with strong PGP9.5 immunopositivity in the compatible population of cells (black arrow).

## Conclusions

Myocardial sleeves in pig arteries consist of myocytes different from normal ventricular myocytes, with abundant expression of PGP9.5, which serves as useful markers for the cardiac conducting system. The myocardial sleeves extending into the aorta and pulmonary artery may contribute to the substrate for OT VTs.

## REFERENCES

- Bunch TJ, Day JD (2006). Right meets left: a common mechanism underlying right and left ventricular outflow tract tachycardias. *J Cardiovasc. Electrophysiol.* 17:1059-1061.
- Crick SJ, Anderson RH, Ho SY, Sheppard MN (1999a). Localisation and quantitation of autonomic innervation in the porcine heart II: endocardium, myocardium and epicardium. *J Anat.* 195(Pt 3):359-373.
- Crick SJ, Sheppard MN, Anderson RH, Polak JM, Wharton J (1996). A quantitative study of nerve distribution in the conduction system of the guinea pig heart. *J Anat.* 188(Pt 2):403-416.
- Crick SJ, Sheppard MN, Ho SY, Erson RH (1999b). Localisation and quantitation of autonomic innervation in the porcine heart I: conduction system. *J Anat.* 195(Pt 3):341-357.
- El SA, Egerbacher M, Hammada AK, Bock P (2001). Immunohistochemical demonstration of Leu-7 (HNK-1), Neurone-specific Enolase (NSE) and Protein-Genes Peptide (PGP) 9.5 in the developing camel (*Camelus dromedarius*) heart. *Anat. Histol. Embryol.* 30:321-325.
- Hachiya H, Aonuma K, Yamauchi Y, Igawa M, Nogami A, Iesaka Y (2002). How to diagnose, locate, and ablate coronary cusp ventricular tachycardia. *J Cardiovasc. Electrophysiol.* 13:551-556.
- Haissaguerre M, Jais P, Shah DC (1998). Spontaneous initiation of atrial fibrillation by ectopic beats originating in the pulmonary veins. *N. Engl. J. Med.* 339:659-666.
- Hasdemir C, Aktas S, Govsa F (2007). Demonstration of ventricular myocardial extensions into the pulmonary artery and aorta beyond the ventriculo-arterial junction. *Pacing Clin. Electrophysiol.* 30:534-539.
- Iwai S, Cantillon DJ, Kim RJ (2006). Right and left ventricular outflow tract tachycardias: evidence for a common electrophysiologic mechanism. *J. Cardiovasc Electrophysiol.* 17:1052-1058.
- Kanagaratnam L, Tomassoni G, Schweikert R (2001). Ventricular tachycardias arising from the aortic sinus of valsalva: An under-recognized variant of left outflow tract ventricular tachycardia. *J. Am. Coll. Cardiol.* 37:1408-1414.
- Lerman BB, Stein KM, Markowitz SM (1996). Idiopathic right ventricular outflow tract tachycardia: a clinical approach. *Pacing Clin. Electrophysiol.* 19:2120-2137.
- Lerman BB, Stein KM, Markowitz SM (1997). Mechanisms of idiopathic left ventricular tachycardia. *J. Cardiovasc. Electrophysiol.* 8:571-583.
- Mansour M, Ruskin J, Keane D (2002). Initiation of atrial fibrillation by ectopic beats originating from the ostium of the inferior vena cava. *J Cardiovasc. Electrophysiol.* 13:1292-1295.
- Ouyang F, Fotuhi P, Ho SY (2002). Repetitive monomorphic ventricular tachycardia originating from the aortic sinus cusp: electrocardiographic characterization for guiding catheter ablation. *J. Am. Coll. Cardiol.* 39:500-508.
- Sadanaga T, Saeki K, Yoshimoto T, Funatsu Y, Miyazaki T (1999). Repetitive monomorphic ventricular tachycardia of left coronary cusp origin. *Pacing Clin. Electrophysiol.* 22:1553-1556.
- Sekiguchi Y, Aonuma K, Takahashi A (2005). Electrocardiographic and electrophysiologic characteristics of ventricular tachycardia originating within the pulmonary artery. *J. Am. Coll. Cardiol.* 45:887-895.
- Shimoike E, Ohnishi Y, Ueda N, Maruyama T, Kaji Y (1999). Radiofrequency catheter ablation of left ventricular outflow tract tachycardia from the coronary cusp: a new approach to the tachycardia focus. *J. Cardiovasc. Electrophysiol.* 10:1005-1009.
- Stevenson WG (2005). Catheter ablation of monomorphic ventricular tachycardia. *Curr. Opin. Cardiol.* 20:42-47.
- Tada H, Naito S, Ito S (2004). Significance of two potentials for predicting successful catheter ablation from the left sinus of Valsalva for left ventricular epicardial tachycardia. *Pacing Clin. Electrophysiol.* 27:1053-1059.
- Tsai CF, Tai CT, Hsieh MH (2000). Initiation of atrial fibrillation by ectopic beats originating from the superior vena cava: electrophysiological characteristics and results of radiofrequency ablation. *Circulation* 102:67-74.