

Casa Report

Misdiagnosis of rupture sites of multiple intracranial aneurysms: Special report of two cases

Zheng Liu*, Liang-feng Wei, Ru-mi Wang and Shou-sen Wang

Department of Neurosurgery, Fuzhou General Hospital, Xihuanbei Road, No 156, Fuzhou, 350025, China.

Accepted 24 November, 2010

Angiography and neurological examination are reliable tools for the identification of rupture in patients with multiple intracranial aneurysms. However, unusual presentation of rupture may cause the false localization of the ruptured aneurysm. We described two cases of bilateral internal carotid artery (ICA) aneurysms that were incorrectly positioned on CT scan. In the first case, CTA revealed bilateral IC-PC aneurysms. According to the localization of injured nerves and findings on radiograph rupture of left aneurysm was diagnosed. The patient suddenly became unconscious 24 h after operation. The cause of death was assumed to be the rupture of the right aneurysm. In the second case, CTA revealed IC-PC aneurysms. The diagnosis of a ruptured right IC-PC aneurysm was made based on neuroradiological findings. However, no rupture or bleeding was found during the operation. Thus the diagnosis of ruptured right IC-PC aneurysm was wrong. In the first case, disastrous re-bleeding occurred before the second operation for the ruptured one. In the second case, the patient died after we performed bilateral craniotomies at the same time. Misjudgment of rupture site by the CT scan resulted in clipping of the wrong aneurysm.

Key words: Bilateral intracranial aneurysm, rupture.

INTRODUCTION

Correct determination of the aneurysm rupture site before operation is crucial for the successful treatment of multiple intracranial aneurysms, particular in multiple complicate aneurysms. Usually, the majority of intracranial aneurysm rupture site can be determined by neurological examination, CT scanning and angiogram. From March 2006 to October 2007, 2 cases of unruptured intracranial aneurysms were misdiagnosed as rupture aneurysm by above-mentioned diagnosis criteria of ruptured intracranial aneurysms.

Case report

Case 1: Female, 31 years, was hospitalized as sudden severe headache, left ptosis, right facial numbness and pain for 1 week. Physical examination: The patient was

conscious and could accurately answer questions, left upper eyelid was ptosed, and the diameter of the left and right pupils was 3 and 2 mm, respectively. Both eyes were sensitive to light. The left eye showed marked limitation of abduction movement. The patient's face was still painful in the area corresponding to V2 and V3 branches of the trigeminal nerve. Four limbs had normal muscular strength and tension. Pathological reflexes were negative. Meningeal irritation signs were present. CT scanning showed bilateral diffuse subarachnoid haemorrhage (SAH), haemorrhage at anterior interhemispheric cistern and cistern of bilateral fissures, without obvious hematoma. Emergency computerized tomographic angiography (CTA) revealed bilateral internal carotid -posterior communicating (IC-PC) aneurysms, and the left aneurysm was conical and about 5 mm×5 mm, and the right one was saccular and about 5 mm×4 mm (Figure 1). The findings of DSA were similar to CTA (Figure 2). According to the level diagnosis of injured cranial nerves and imaging findings, it was diagnosed that the left aneurysm was ruptured. Interventional therapy was not chosen because the patient could not

*Corresponding author. E-mail: zhengjh0471@163.com. Tel: 86-591-85661888. Fax: 86-591-85661888.

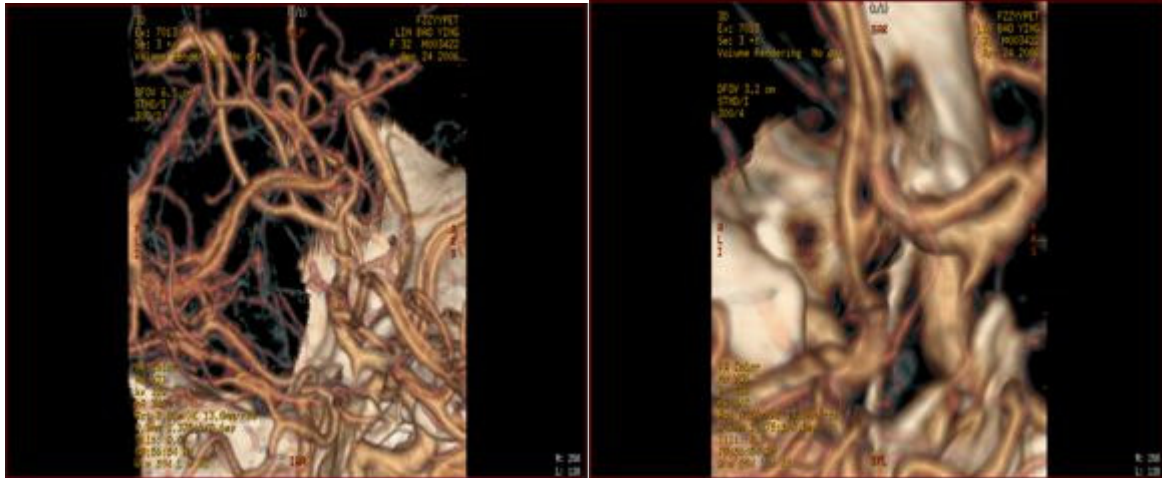


Figure 1. Preoperative CTA revealed bilateral IC-PC aneurysms.

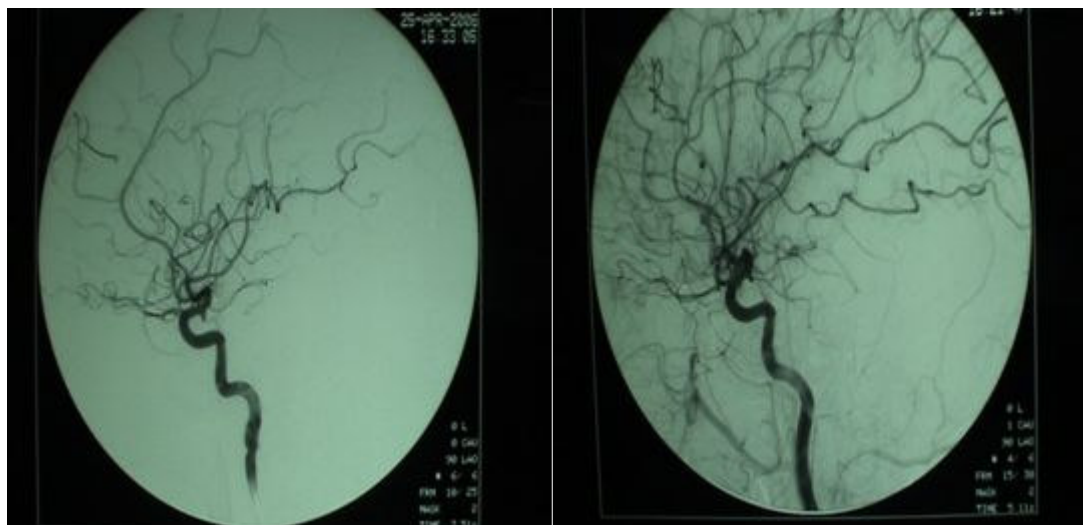


Figure 2. Preoperative DSA revealed bilateral IC-PC aneurysms.

afford the cost. The left pterion approach was made for the clipping of aneurysm under general anesthesia in the next day. There was almost no bleedings in the left chiasmatic cistern and carotis cistern. The IC-PC aneurysm was isolated from surrounding tissues and then clipped on the neck of aneurysm. The blood circulation of anterior choroidal artery and posterior communicating artery was good. The wall of the aneurysm was thick and there was no rupture (Figure 3). The operation was successful, and the patient recovered well after operation. Suddenly, the patient became unconscious at 24 h later, with dilated right pupil. The patient died in spite of active salvage, and the cause of death was assumed to be the rupture of the right aneurysm.

Case 2: female, 65 years, was hospitalized as sudden headache and unconsciousness for 5 days. Physical

examination: the patient was drowsy, but could be aroused sufficiently to answer questions. The diameters of the two pupils were 2.5 mm. The pupils were reactive to light. The movement of eye balls was normal. There was no palsy of facial muscles. Four limbs had normal muscular strength and tension. Pathological reflexes were negative, and meningeal irritation signs were present. CT scanning showed diffuse SAH at basal cisterns. Bleeding in the anterior interhemispheric cistern and right sylvian cistern was comparatively obvious (Figure 4). Emergency revealed bilateral IC-PC aneurysms, and the left aneurysm was saccular and about 5 mm×4 mm, and the right one was conical and about 5 mm×6 mm in size (Figure 5). The diagnosis of right ruptured IC-PC aneurysm was made based on the above neuroradiological findings. Interventional therapy was not chosen because of too high cost. The right

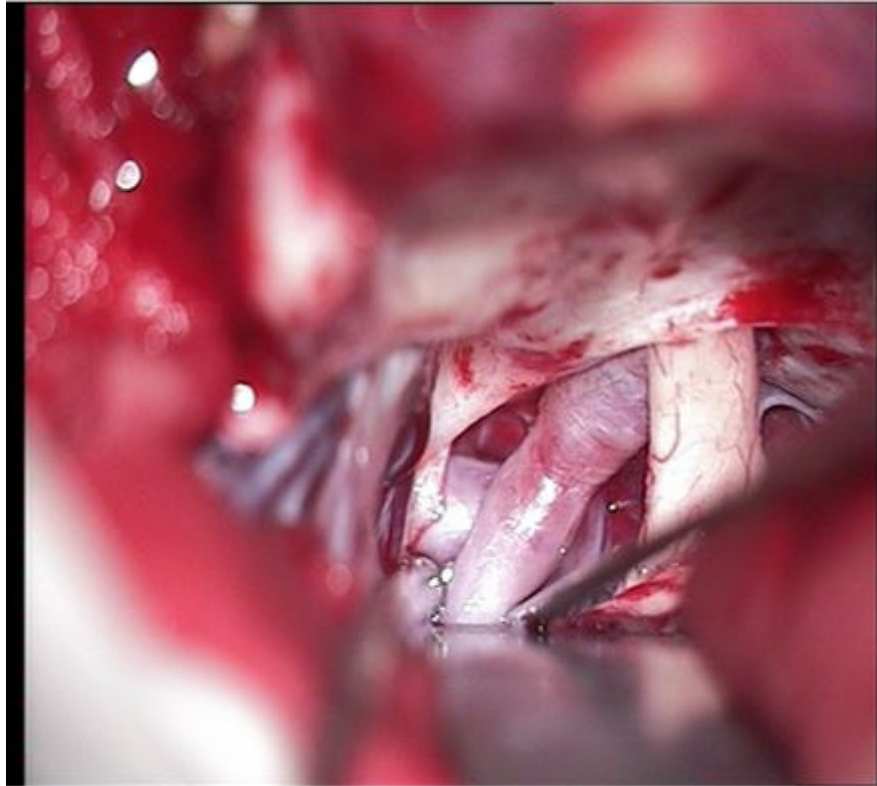


Figure 3. Craniotomy at left pterion showed that aneurysm was unruptured.

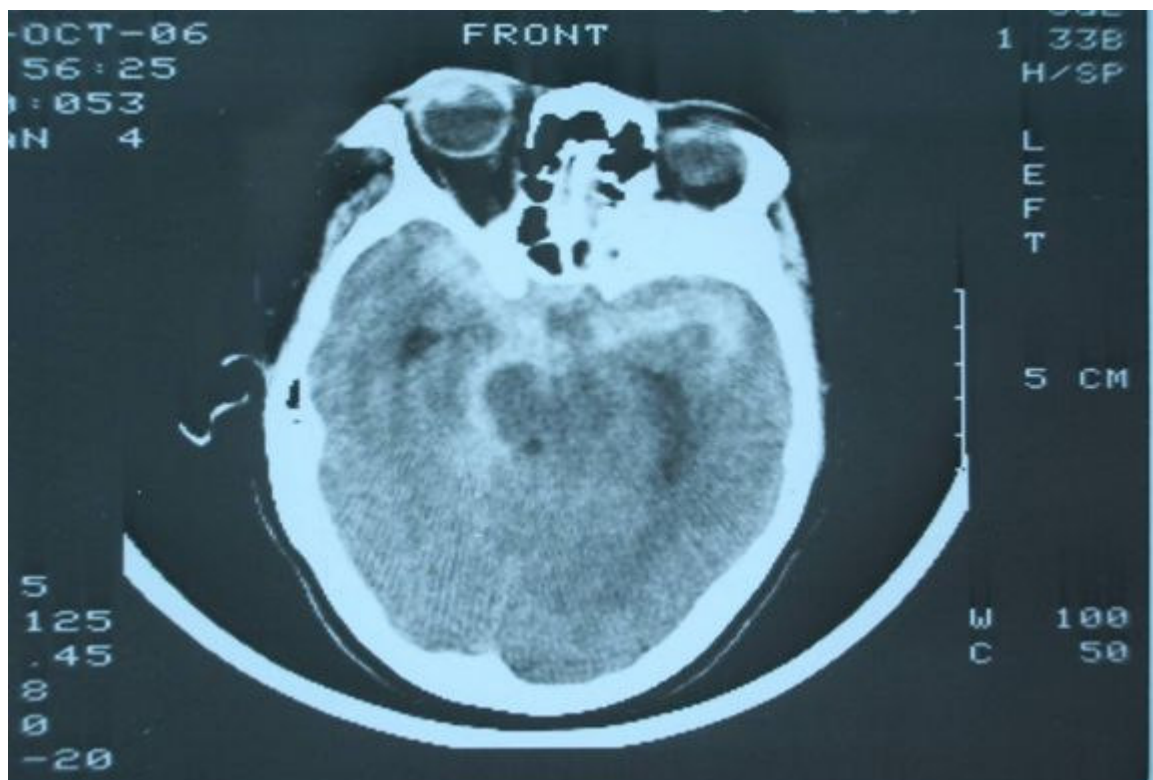

Figure 4. The patient, female, 65 years old. Preoperative CT scanning showed SAH.

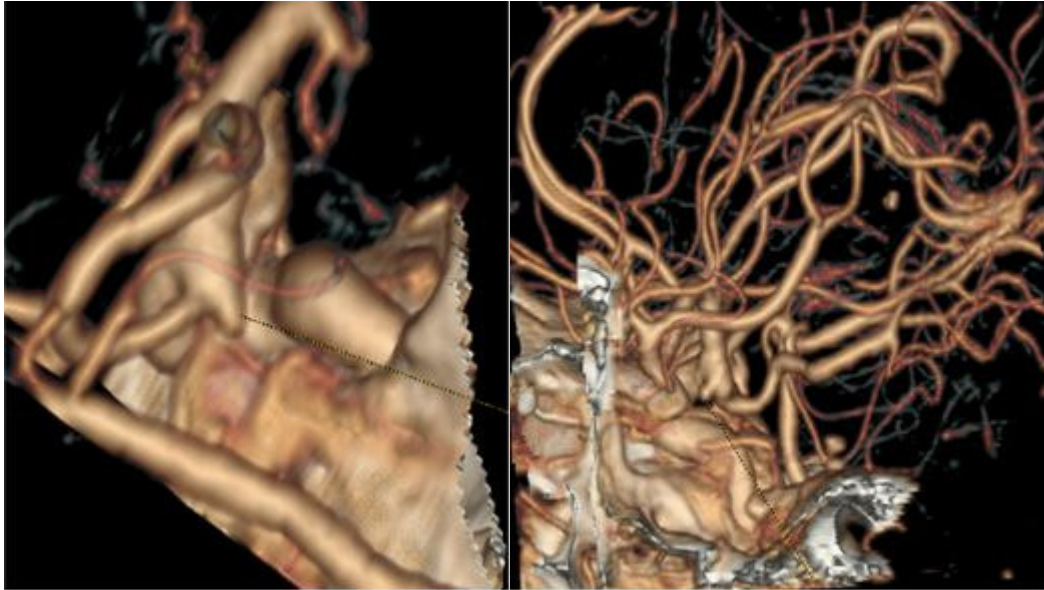

Figure 5. Preoperative CTA revealed bilateral IC-PC aneurysms.

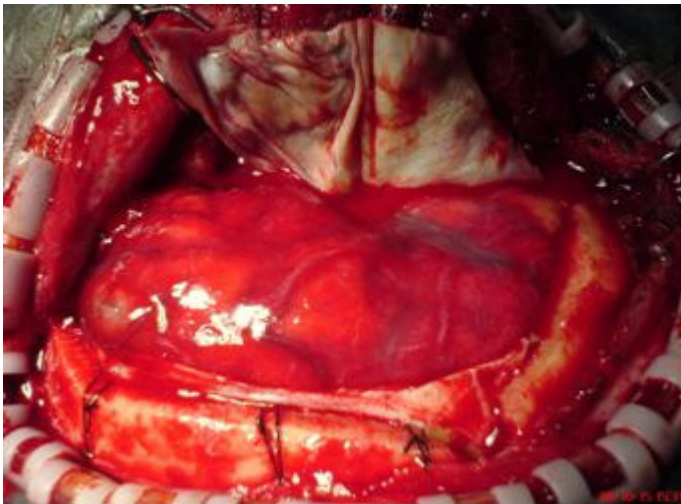


Figure 6. Craniotomy at left and right pterion showed that aneurysm was unruptured.

pterior approach was made for the clipping of aneurysm. There was marked bleeding at right cerebral cortex during operation (Figure 6) and a small quantity of hematoma at chiasmatic and carotid cisterns. A vesiculiform right IC-PC aneurysm 5 mm × 6 mm in size was isolated, and clipped at the neck of aneurysm. Then, it was found that the blood circulation of anterior choroidal artery and posterior communicating artery was good. However, further dissection revealed that the aneurysm wall was thick and there was no rupture or bleeding. Thus we concluded that the preoperative diagnosis of ruptured right IC-PC aneurysm was

misdiagnosed, and then the patient immediately received left pterion craniotomy. When the dura mater was incised, the blood pressure of the patient dropped dramatically to 50/26 mmHg, and blood pressure increased to 110/50 mmHg after administration of hypertensive agents and blood transfusion. Bleeding was observed at left cerebral cortex, but less than that at right cerebral cortex (Figure 6). Later, a left IC-PC aneurysm with a small rupture was identified and clipped at the neck of aneurysm. Unfortunately, the patient remained unconscious for 3 days after operation, and her family members gave up the treatments.

DISCUSSION

Multiple intracranial aneurysms refer to two or more simultaneously presenting intracranial aneurysms. Thus, the rupture rate of multiple aneurysms and its mortality rate are significantly higher than that of single intracranial aneurysm. Recently, the detection rate of multiple intracranial aneurysms is increased significantly, and multiple intracranial aneurysms are diagnosed in 15 to 45% of SAH patients (Ellamushi et al., 2001; Kaminogo et al., 2003; Bai-nan et al., 2005).

Before operation, precious determination of the rupture site of multiple intracranial aneurysms is crucial for successful treatments, especially in aneurysms which cannot be clipped through one operative approach. Generally, the following features can accurately predict the ruptured aneurysms (Hino et al., 2000; Liu, 2000; Nehls et al., 1985): (1) Nervous system symptoms: there are lateralizing or localizing symptoms in 30% ruptured aneurysms, such as facial palsy, paralysis, hemiplegia,

aphasia and oculomotor palsy; (2) CT or MRI: blood of subarachnoid hemorrhage was mainly distributed around ruptured aneurysm, and thus hematoma is the sign of aneurysm rupture site; (3) DSA or CTA: ruptured aneurysms are usually complicated with hematoma, cerebral edema and cerebral infarction, and thus some local arteries are moved, and aneurysm artery and surrounding artery is partially contracted; (4) Morphology of aneurysms: bleeding aneurysm (87%) is usually the larger one of bilateral aneurysms or the largest of multiple aneurysms. The morphology of ruptured aneurysms is irregular, presenting lobulated and uneven filling. If there are two aneurysms in one artery, the proximal aneurysm is mostly ruptured.

In summary, the ruptured aneurysm can be diagnosed by the size of aneurysm in 87% patients. Besides, ruptured aneurysms can be diagnosed by the irregular morphology, arterioplegia and vasospasm in the 8% of remaining patients. Thus, 95% of ruptured aneurysms can be diagnosed. Hino et al. (2000) emphasized the irregular morphology of aneurysm such as lobulated, child-mother and prolapse aneurysms, especially with child-mother aneurysm plays important roles in the diagnosis of ruptured aneurysm. Nehls et al. (1985) believed that aneurysm rupture site could be correctly determined according to the above criteria.

However, the above criteria hardly predict the rupture site in 2-5% multiple aneurysms. In the study of Inagawa et al. (1991), 13 small unruptured aneurysms were not found by preoperative imaging examinations in 12 cases of multiple aneurysms following SAH, and they were observed after the removal of hematoma and palliation of cerebral angio spasm. Hino et al. (2000) reported that, of 93 cases of multiple aneurysms, ruptured aneurysm was not diagnosed in 6 cases, and the remaining ruptured aneurysm was missed in 5 cases because one aneurysm had been observed in 1st angiography, and 4 cases suffered from rehaemorrhagia. In this study, case 1 developed left abducent nerve and oculomotor nerve palsy after final diagnosis of SAH. Both DSA and CTA reveal that posterior communicating aneurysm was irregular, and right trigeminal nerves were mildly injured. But craniotomy confirmed that the left aneurysm was unruptured. In case 2, SAH at unruptured aneurysm side was more obvious than that at ruptured side, which was

rare in clinical practice, indicating that current diagnostic criteria still hardly diagnose the accurate puncture site of a very small number of multiple aneurysms. Up to now, the detailed mechanisms are unknown.

If the rupture site of multiple aneurysms cannot be predicted and bilateral aneurysms cannot be clipped by unilateral craniotomy, interventional therapy and embolotherapy should be given as soon as possible (Xiong et al., 2005). If interventional therapy and embolotherapy are unfeasible or hardly performed, emergency surgical exploration should be carried out. If the clipped aneurysm is the unruptured one, the contralateral aneurysm should be clipped by contralateral approach or by a separate craniotomy. In case 1, we were afraid that she could not endure the damage of bilateral craniotomies, but the optimal treatment opportunity was missed. In case 2, we decided to perform contralateral craniotomy based on our experience in case 1. But the patient eventually died of the surgical trauma. Thus, interventional therapy and embolotherapy should be the first treatment choice especially in older patients.

REFERENCES

- Bai-nan X, Zheng-hui SUN, Ding-biao ZHOU (2005). Surgical treatment of multiple intracranial aneurysms. *Chi. J. Neurosurg.*, 21: 647-649.
- Ellamushi HE, Grieve JP, Jäger HR, Kitchen ND (2001). Risk factors for the formation of multiple intracranial aneurysms. *J. Neurosurg.*, 94: 728-732.
- Hino A, Fujimoto M, Iwamoto Y, Yamaki T, Katsumori T (2000). False localization of rupture site patients with multiple cerebral aneurysms and subarachnoid hemorrhage. *Neurosurg.*, 46: 825-830.
- Inagawa T (1991). Surgical treatment of multiple intracranial aneurysms. *Acta Neurochir. (wien)*, 108: 22-29.
- Kaminogo M, Yonekura M, Shibata S (2003). Incidence and outcome of multiple intracranial aneurysms in a defined population. *Stroke*, 34: 16-21.
- Liu CJ (2000). *Cerebrovascular Surgery*. Jiangsu Province: Jiangsu Science and Technology Press, pp. 134-135.
- Nehls DG, Flom RA, Carter LP, Spetzler RF (1985). Multiple intracranial aneurysms: determining the site of rupture. *J. Neurosurg.*, 63: 342-348.
- Xiong JR, Wang YB, Wang QX (2005). Ruptured and hemorrhagic intracranial aneurysm was treated by detachable coil embolization. *Chi. J. Neurosurg.*, 21: 493-494.